

DES ANATOMISCHEN

BILDER

VON

Dr. med. Szymanowski

1857.

DORPAT.

**DESMOLOGISCHE**  
**BIJOUER**  
zum

*Selbstunterricht*

von

**D<sup>r</sup> Szymanowski**

Privatdocent an der Kaiserlichen Universität  
zu Dorpat & Assistent-Arzt der chir. Klinik daselbst.

---

**198**

*Abbildungen auf 27 Tafeln*

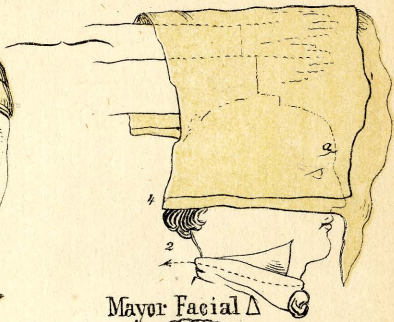
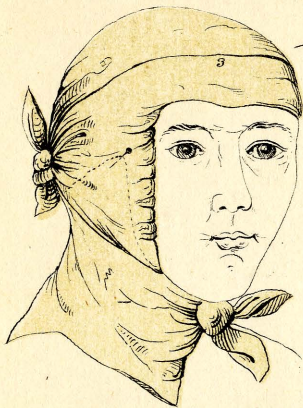
Auf Stein gezeichnet von C. Schulz

in

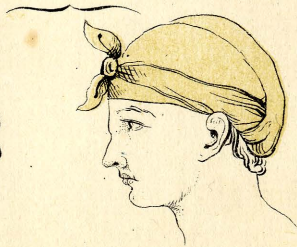**DORPAT**

**1857.**

## Capitium magnum, quadrangulare.

Mayor: Facial  $\Delta$ 

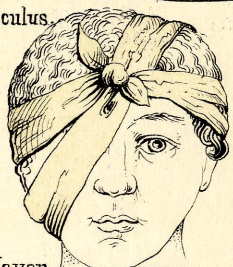
## Capitium parvum, triangulare



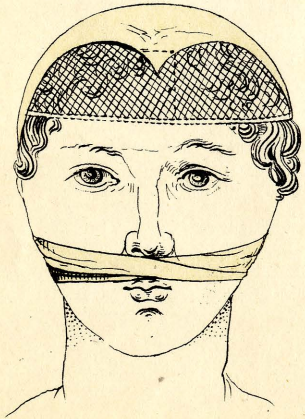
Schröger's Kopfbinde



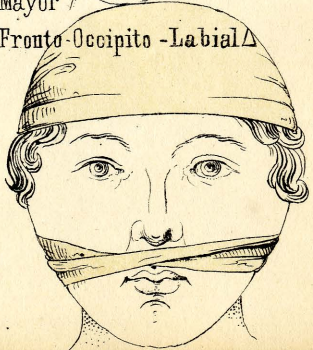
Monoculus.



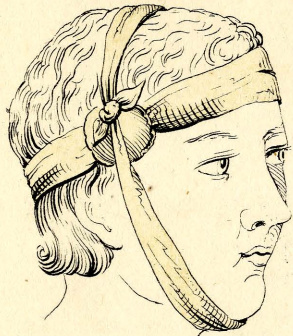Mayor Occipito-Labial Δ




Mayor Fronto-Occipito-Labial Δ




Fascia nodosa



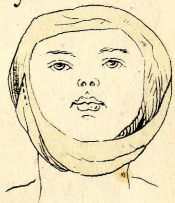Capistrum.

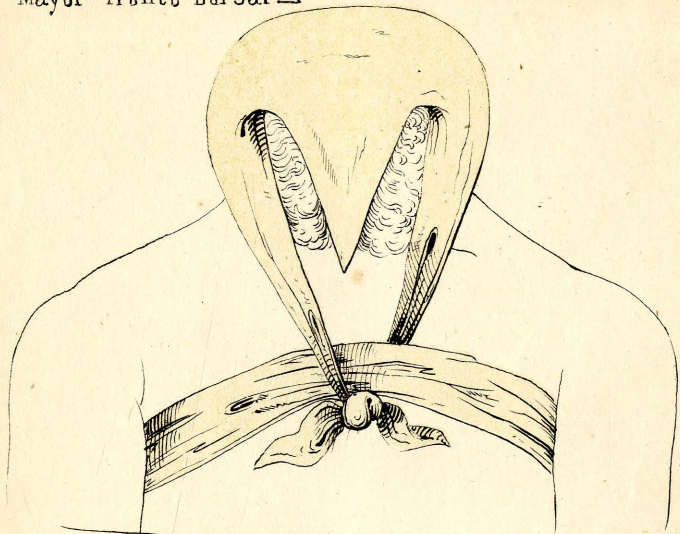


Mayor Occipito-Sternal  $\Delta$

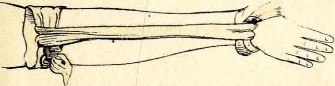


Mayor fundament.

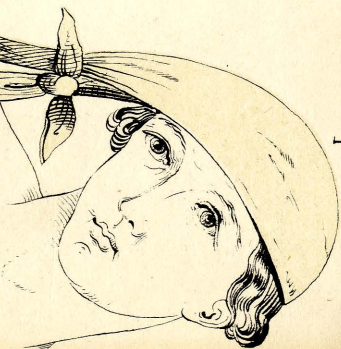



Mayor  
Cravates carpo-olécraniennes.



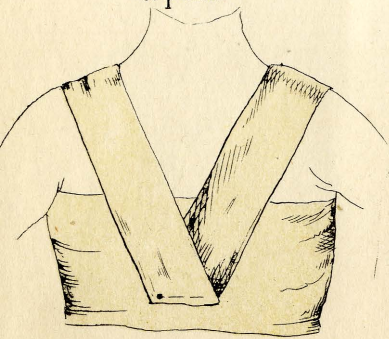
Temporal-Axillar  $\Delta$



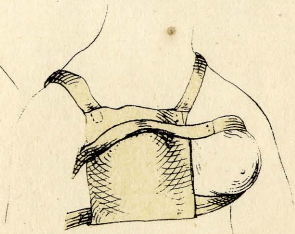
Mayor  
Cingulum pectoris



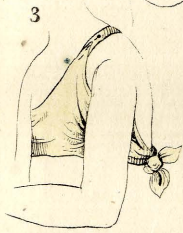
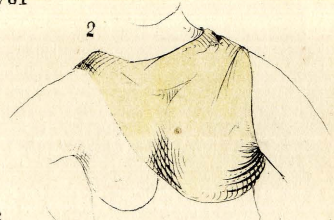
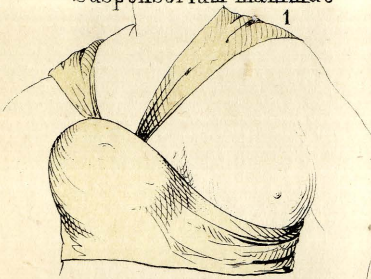
Scapulier



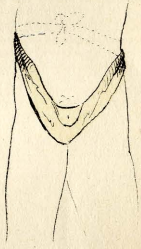
Suspensorium mammae  
compositum



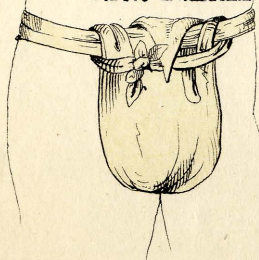
Suspensorium mammae Mayor



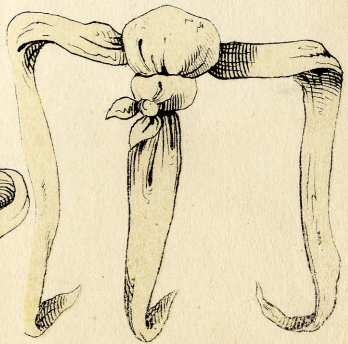
Mayor Scroto-Lumbal Δ



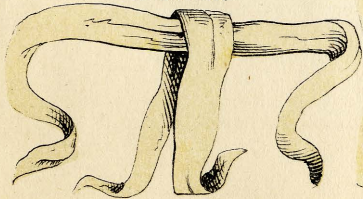
Mayor Scroto-Lumbal Δ



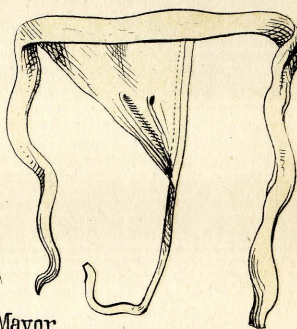
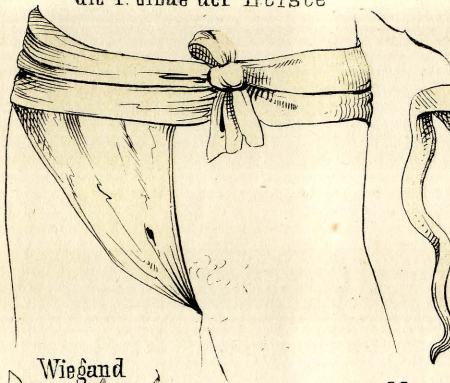
Bruchband.



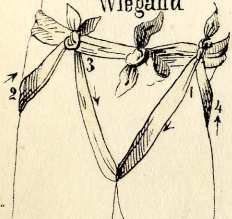
T. Binde.



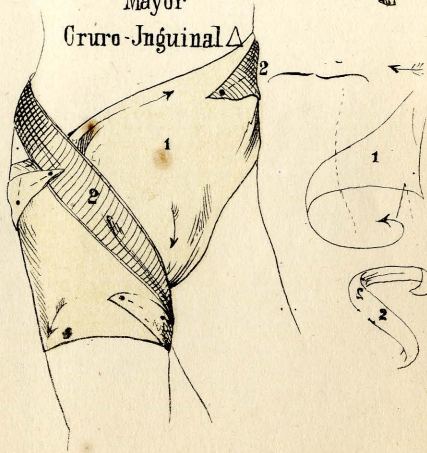
die T. binde der Leiste



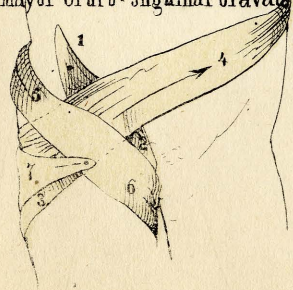
Wiegand



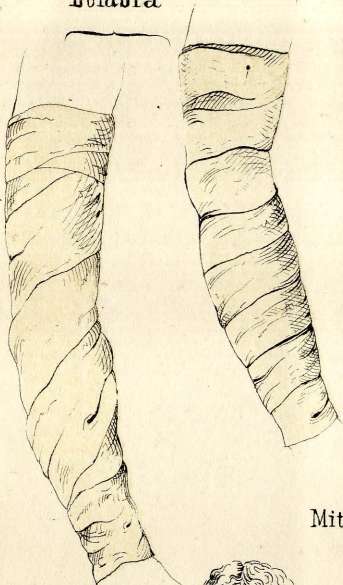Mayor Cruro-Inguinal  $\Delta$



Mayor Cruro-Inguinal Cravate



Dolabra




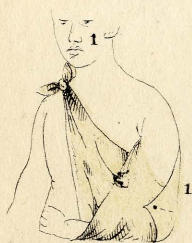
Cravate bis-axillaire

VIII



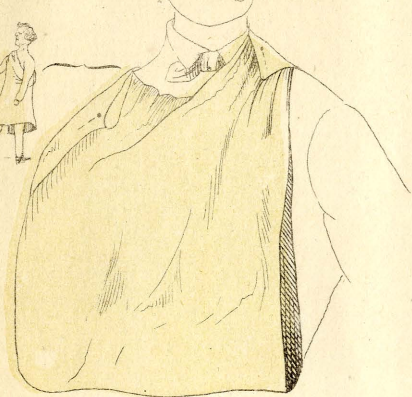
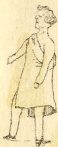Vinculum  
humero-cervicæ

Mitella triangularis

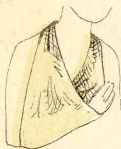

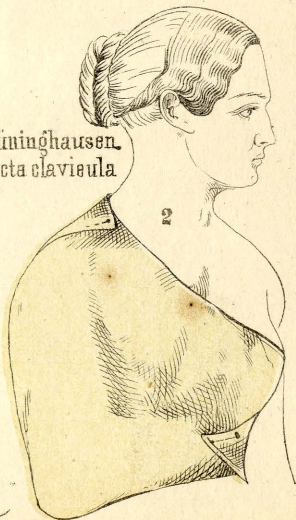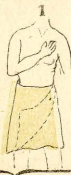
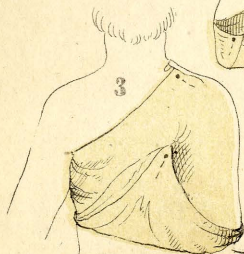
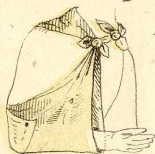


Mitella

Mitella quadrangularis .



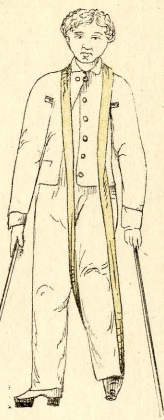
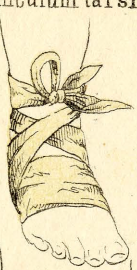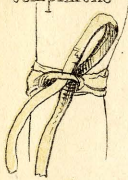
Mitella parva

Brüninghausen.  
pro fracta clavieula

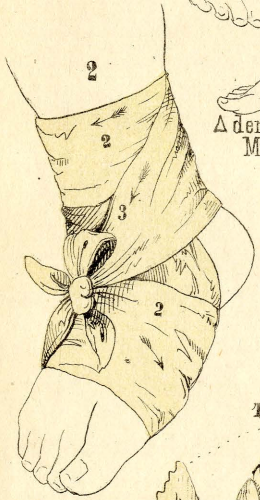
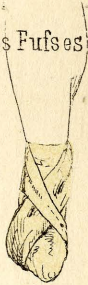


F. ante venaesect.  
compimens

Vinculum tarsi

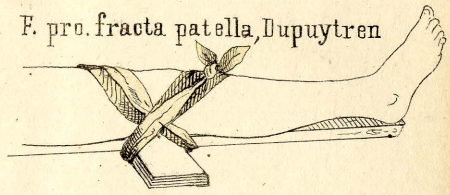


Δ des Fusses Mayor

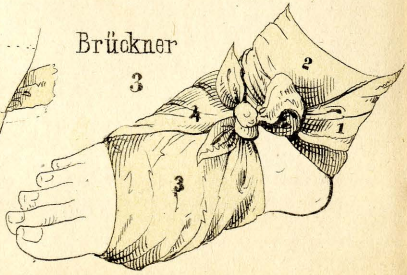
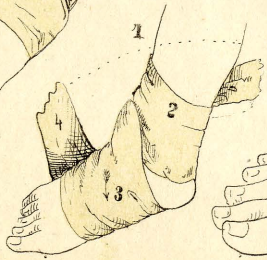


Δ der Ferse Mayor

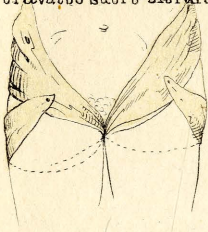
F. pro. fracta patella, Dupuytren



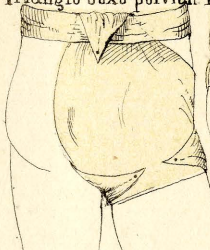
Brückner



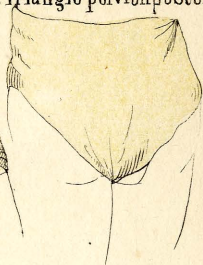Mayor  
cravates sacro-bierurales



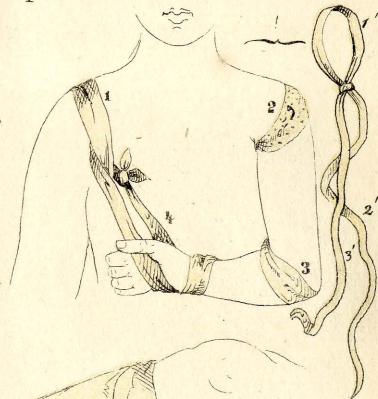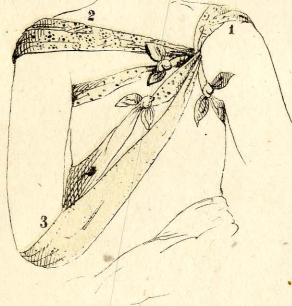
Mayor  
Triangle coxo-pelvien



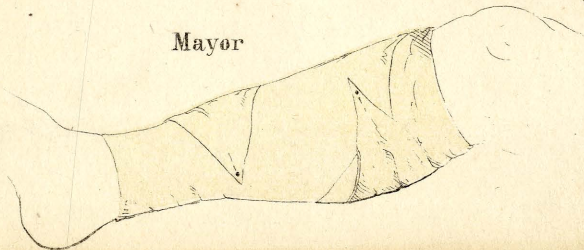
Mayor  
Triangle pelvienposterieur


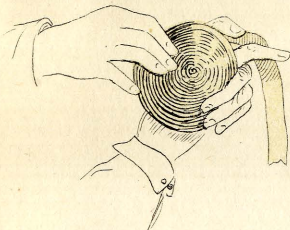


Szymanowski  
Vinculum pro fracta clavicula

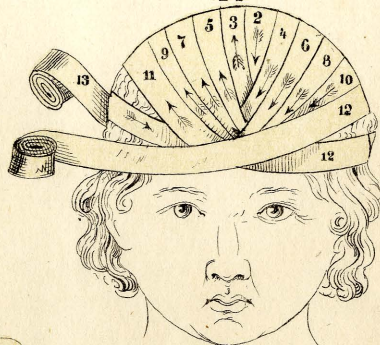
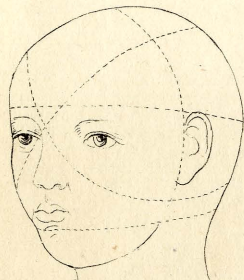


Mayor

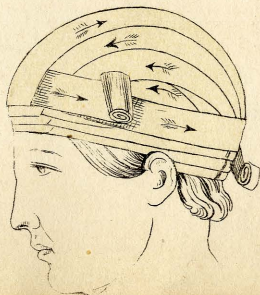



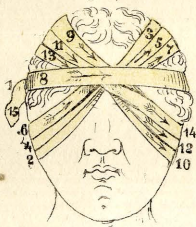
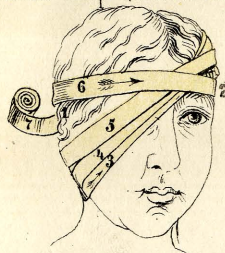
Mitra Hippocratis



F. nodosa



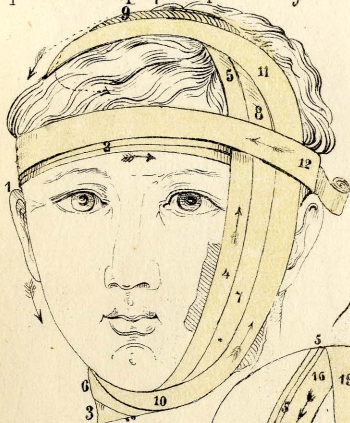
Focul. simpl. (Monoculus) F.o. dupl. (Oculus duplex)




F. uniens capitis



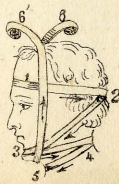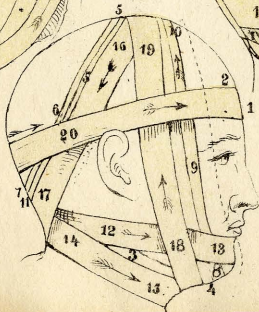
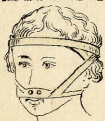Capistrum simpl. prof. proc. condyl.



Capistrum dupl.

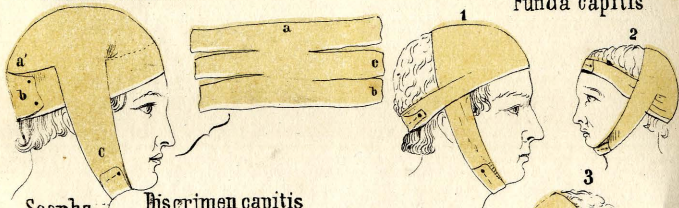


Funda nasalis



Cancer Galeni.

Funda capitis



Scapha.

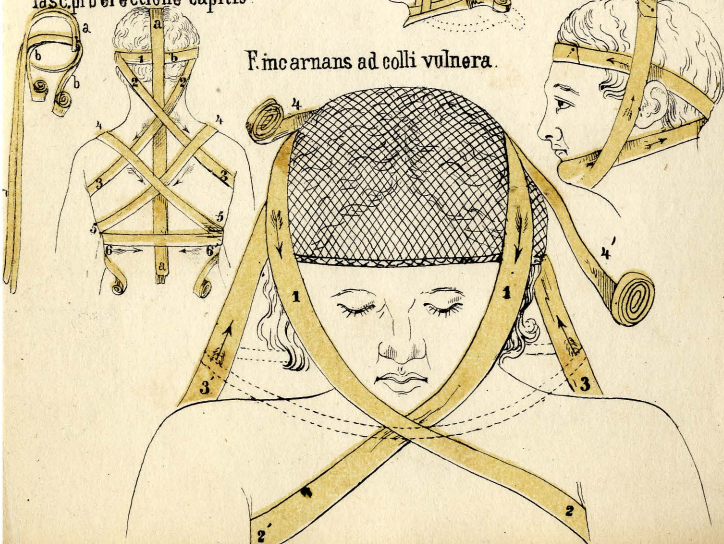
Bis crimen capitis.

F. continens colli.

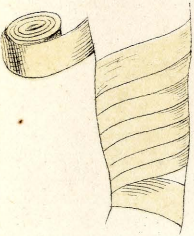


Fasc. pro erectione capitis.

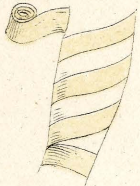F. incarnans ad colli vulnera.



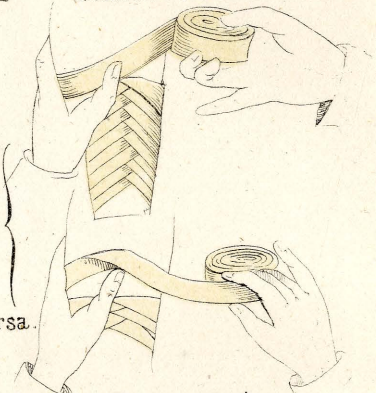
Dolabra



Dolabra repens

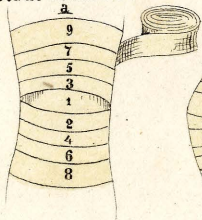


Dolabra reversa

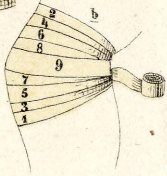


F. circularis.

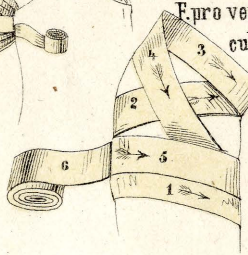
Testudo reversa.



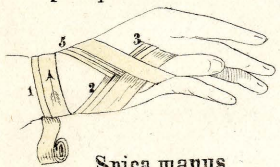
Testudo inversa.



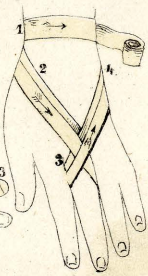
F. pro venae. in cubito.



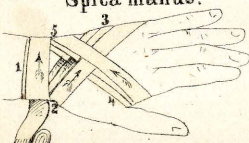Spica pollicis.



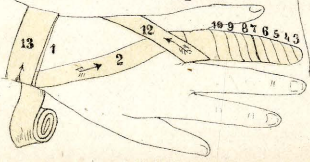
Chirotheca dimid



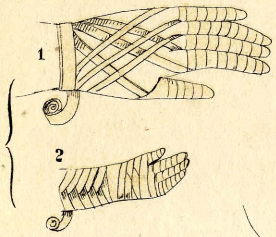
Spica manus.



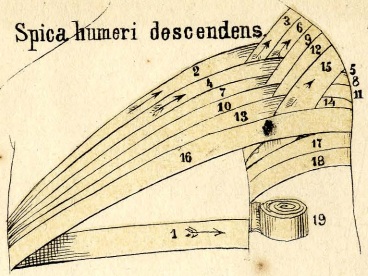
Chirotheca incompleta



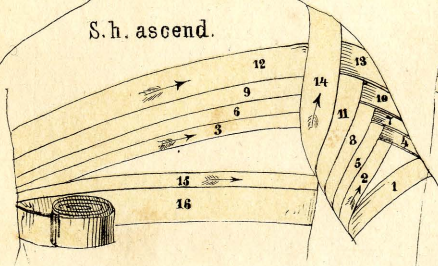
Chirotheca



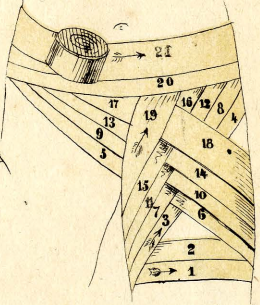
Spica humeri descendens



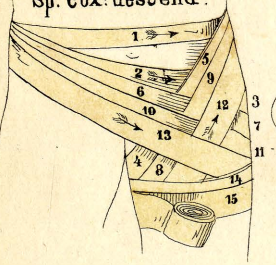
S. h. ascend.



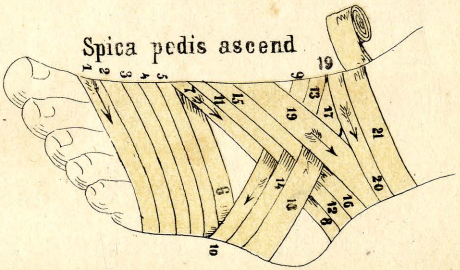
Spica coxae ascend



Sp. cox: descend.

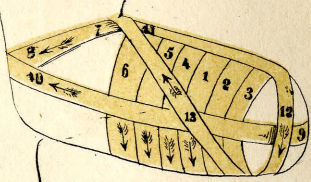
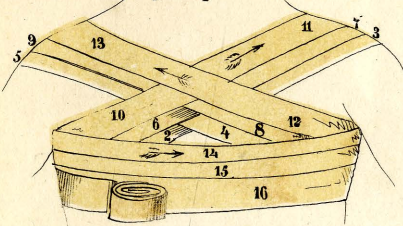


Spica pedis ascend

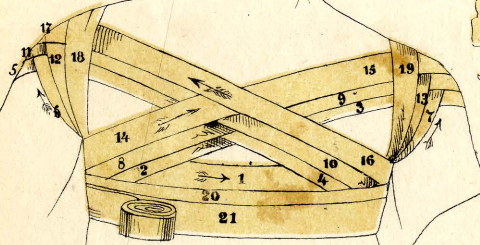



Spica pectoris

F. membri curti reflexa capite simplici

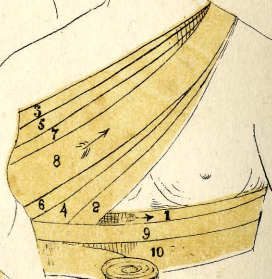


Spica pectoris et dorsi.

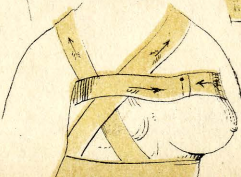
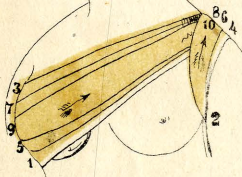


Suspensorium mammae simpl

Suspens. mammae simpl



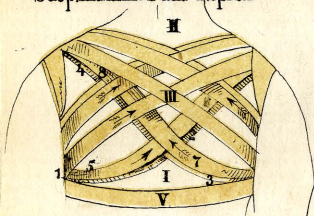
Susp. mammae e fasc. T duplici



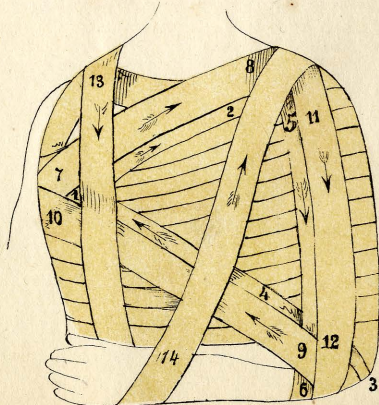
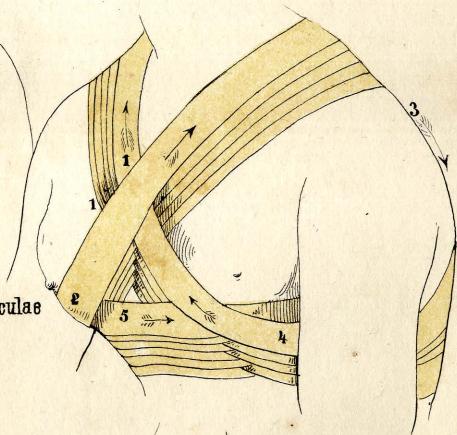
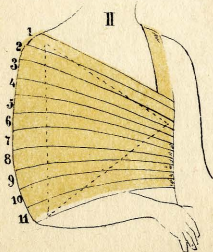
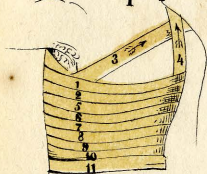
Fasc. compressa

Susp. mammarum duplex

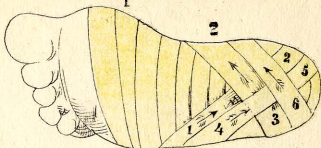
Suspensorium mammar. duplex



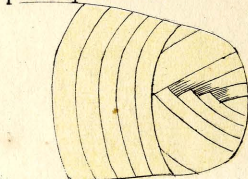
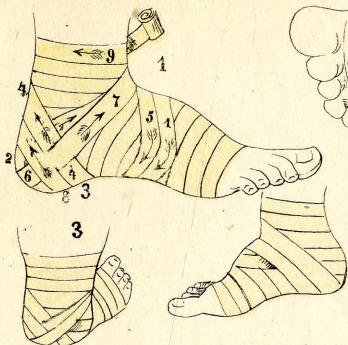
Desault  
I F.p. fract. claviculae



Spica calc

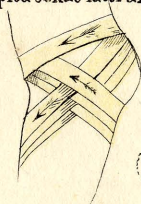
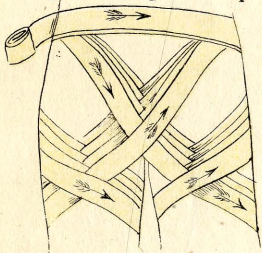


Epro amputatione.

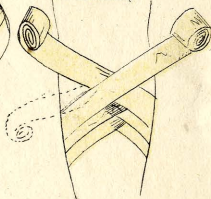


Spica coxae poster. dupl

Spica coxae lateral

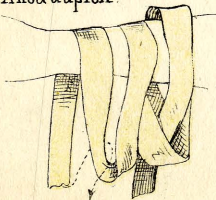


F. uniens.

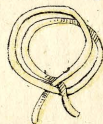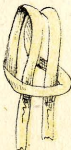


Ansa obliqua

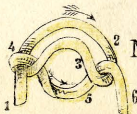
Ansa duplex



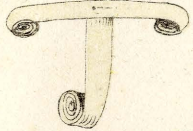
Ansa simplex



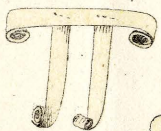
Nodus textorius



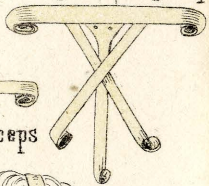
F. T formir




F. T form dupl



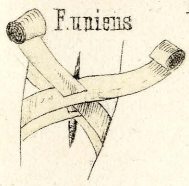
Accipiter quinqueceps



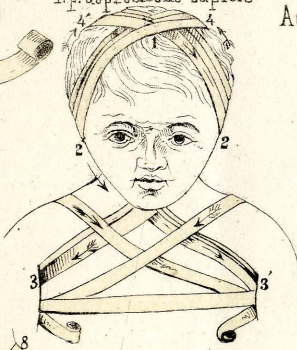Accipiter triceps



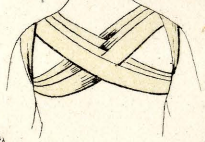
F. uniens



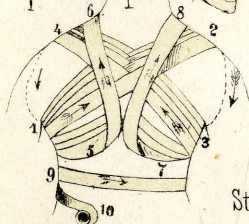
Ep. depressione capitis



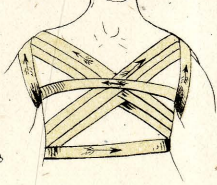
Stella dorsi



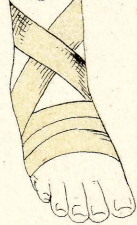
Susp. mam. dupl



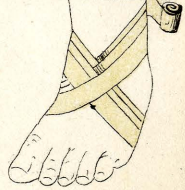
Stella pectoris



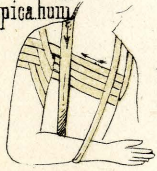Stapes



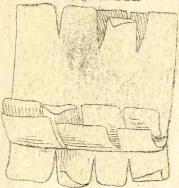
Sandalium



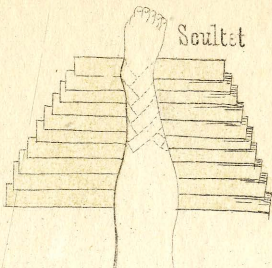
Spica humi



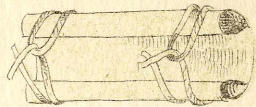
Löffler



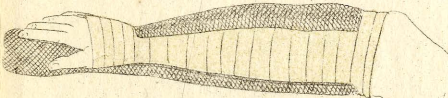
Seultet



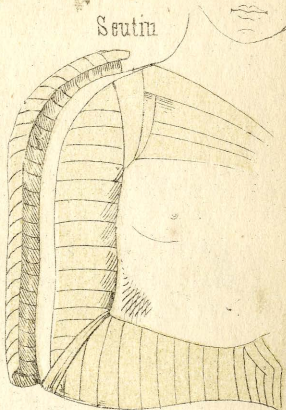
Lectulus stramineus



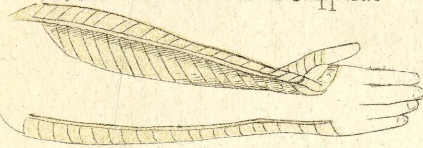
Seutin's Kleister-Verband.



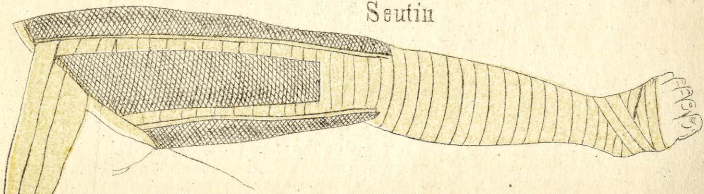
Seutin



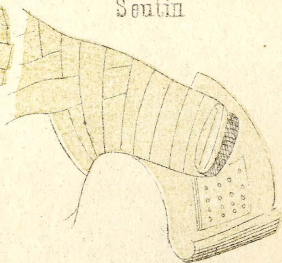
Seutin's amovo-inamovibler Apparat



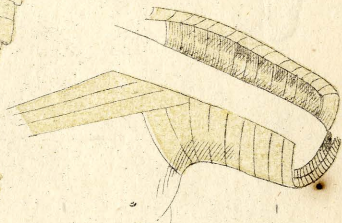
Seutin



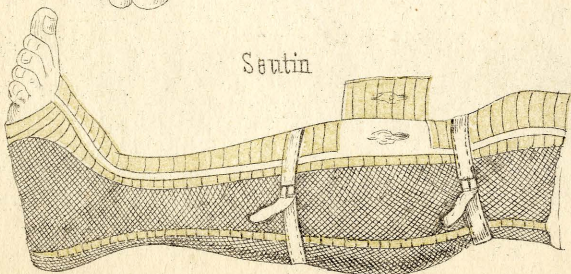
Seutin



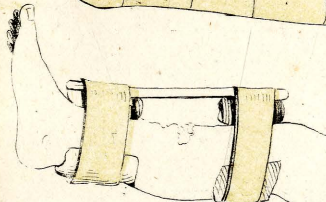
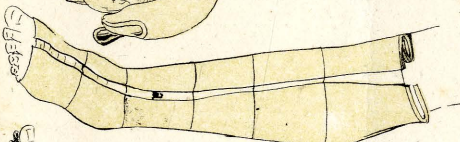
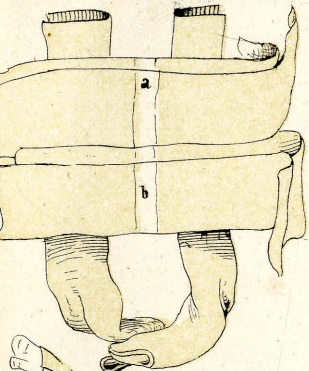
Seutin



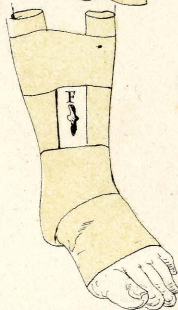
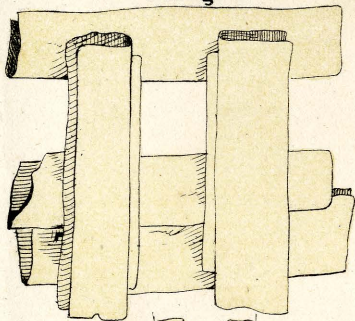
Seutin



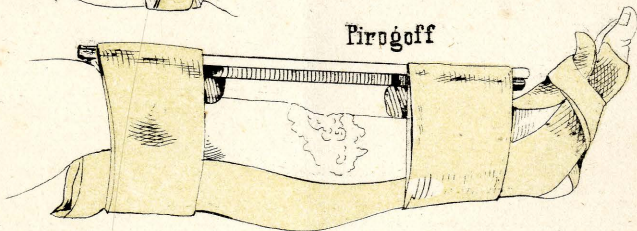
Piröhoff's Gypsverband



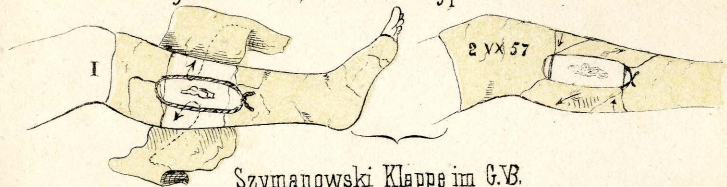Piröhoff



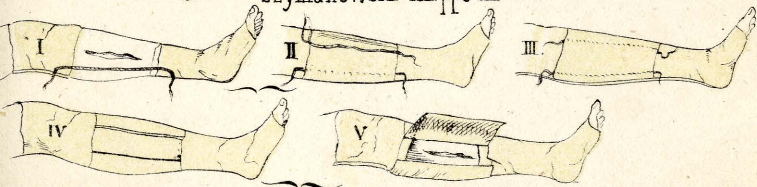
Piröhoff



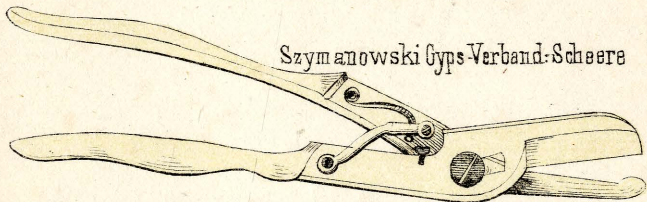
## Szymanowski, Fenster im Gypsverbande



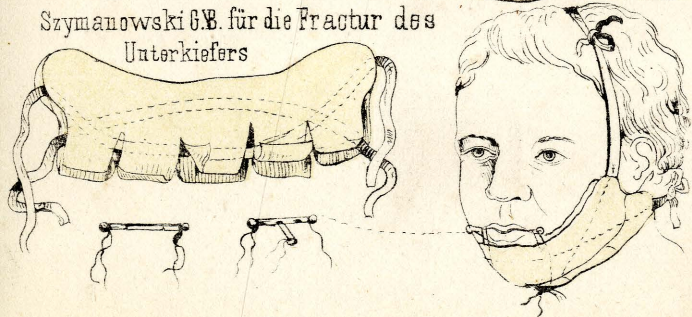
## Szymanowski Klappe im G.V.

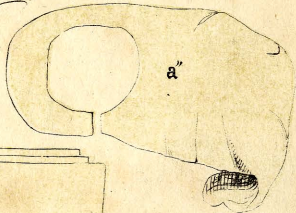
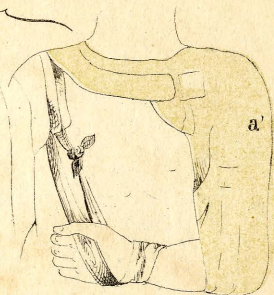
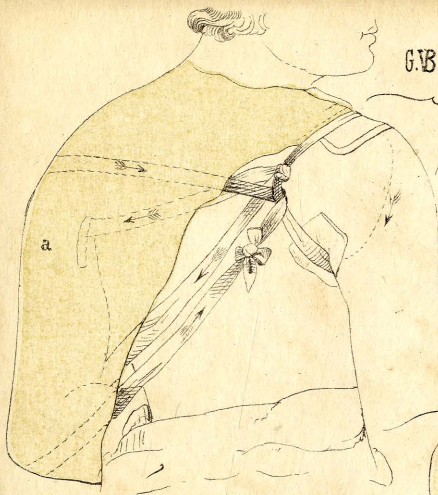


## Szymanowski Gyps-Verband-Schere



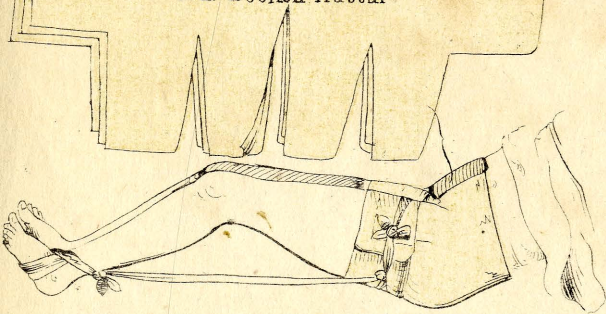
## Szymanowski G.V. für die Fractur des Unterkiefers

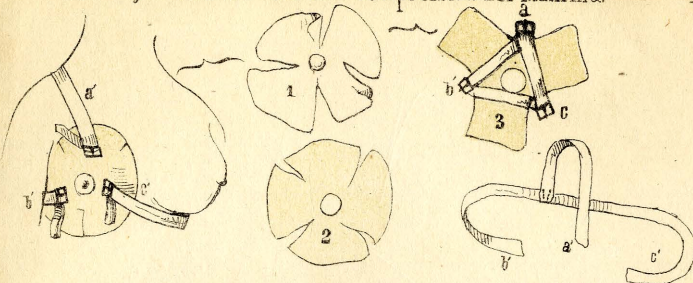




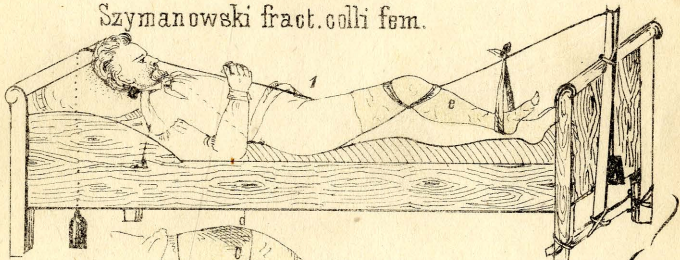Szymanowski,

G.V. Becken fractur





Szymanowski fract. colli fem.



Szymanowski p.fr. humeri

