

ESTICA | A-7223  
LABORATORY OF ANIMAL HISTOLOGY AND EMBRYOLOGY,  
UNIVERSITY OF TARTU, ESTONIA

---

---

**THE MICRO-RELIEF ELEMENTS OF  
THE STOMACH AND INTESTINE IN  
DOMESTIC MAMMALS**

BY

**PROFESSOR DR. JUL. TEHVER**

WITH 44 PHOTOGRAPHIC FIGURES IN 7 TABLES

---

TARTU 1939

ESTICA

A-7223



LABORATORY OF ANIMAL HISTOLOGY AND EMBRYOLOGY,  
UNIVERSITY OF TARTU, ESTONIA

---

THE MICRO-RELIEF ELEMENTS OF  
THE STOMACH AND INTESTINE IN  
DOMESTIC MAMMALS

BY

PROFESSOR DR. JUL. TEHVER

WITH 44 PHOTOGRAPHIC FIGURES IN 7 TABLES

---

TARTU 1939



*Acta et Commentationes Universitatis Tartuensis (Dorpatensis) A XXXIV.9.*

## INTRODUCTION <sup>1</sup>.

According to the layers of the wall participating in the moulding of the relief of the gastro-intestinal tract, JACOBS-HAGEN (1937) distinguishes between: (1) the propria relief, embracing the unevenness of the propria alone, (2) the Kerckring relief, produced by the foldings of the submucous layer, (3) the Esch relief, formed by the macroscopic transversal folds of the intestine, and comprising besides the mucous membrane also the circular layer of the muscularis, and (4) the relief formed by the semilunar folds, which is peculiar only to the large intestine possessing taeniae.

A more detailed specification of the relief-forms produced by the mucous membrane alone originates from FORSELL (1928), a Swedish professor, who has classified them as high-, level-, and micro-reliefs (Hoch-, Flach- und Mikro-relief). A high-relief is produced by the foldings of the mucous membrane, involving also the submucous layer. A level-relief is produced by the foldings of the propria or the glandular layer alone. The high- and the level-reliefs together form the macro-relief. The macroscopic folds of the mucous membrane form the elements of the high-relief, and the level-relief is to be found for instance in the form of the gastric areas and the furrows between them. The micro-relief is produced by the unevenness of the free surface of the propria in the form of tiny depressions and elevations. Gastric pits or foveolae and interfoveolar septa are the elements of this class of the relief in the stomach, and in the

---

<sup>1</sup> Grants from the Funds of the Tartu University Graduates have been awarded to the author to enable him to procure the animal and photographic material necessary for the present work, for which the author herewith desires to express his grateful acknowledgement to the governing board of the abovementioned funds.

intestine it is formed by the surface pierced through with the gland openings together with the villi or microscopical folds in the small intestine. FORSSELL's level-relief together with his micro-relief corresponds to JACOBSHAGEN's propria-relief, and FORSSELL's high-relief to the latter's Kerckring relief.

In the present paper we are interested only in those elements of the relief of the mucous membrane in the gastro-intestinal tract, which in FORSSELL's terminology form the micro-relief, viz., the surface formations of the propria, which are due not to the irregular thickness of the propria, but embrace only its surface in the form of microscopic depressions and elevations.

Particularly during the last two decades appropriate attention has been bestowed upon the relief of the digestive tract in general and also upon the micro-relief. Preeminent in this department are the above mentioned works by FORSSELL and JACOBSHAGEN; the former primarily endeavours to elucidate the mechanism of the high- and level-reliefs of the human gastro-intestinal tract, whilst the latter is interested in the relief picture of the intestine in various representatives of the vertebrates. JACOBSHAGEN presents a clear survey of the results of his own researches in the relief and those of others in volume III of the work edited by Bolk, Göppert and others: „Handbuch der vergleichenden Anatomie der Wirbeltiere“, 1937 (Rumpfdarm, pp. 563—724), and supplies them with numerous photomicrographic illustrations.

No such interest has recently been shown in the relief of the digestive tract of the domestic mammals. With the exception of a manuscript work (VAU, 1932) all the research work in the relief of the small intestine in domestic mammals comes from the end of the last or the first decade of the present century (SCHRIEVER, 1899; MARTIN, 1906; BUJARD, 1909; MATTHIAS, 1910). In the works just mentioned we find a rather detailed description of the micro-relief of the small intestine, but in view of the fact that the shape of the relief elements is frequently irregular, it is very difficult to obtain a correct idea of what they are like from a mere verbal text, for, with the exception of BUJARD's work, the relief has not been demonstrated photographically in surface-view elsewhere. Illustrations representing the surface relief of the gastro-intestinal tract spatially are missing also in ELLENBERGER's manual of microscopical anatomy (1909),

and, with very few exceptions, in MÖLLENDORFF's manual of human microscopical anatomy (1936), to say nothing of the textbooks of histology which follow these examples.

But the lack of appropriate illustrations which represent the relief plastically is not the only shortcoming of the earlier research works. There are many facts which entail a partial untrustworthiness of their descriptions, such as the macroscopic method of research employed by SCHRIEVER in studying the form of villi, the disregard of possible differences in the relief picture depending on the different parts of the intestine, or the age of the animal (young or adult), and presumably a deficient technique in the stretching of the intestinal wall or in the removal of the mucous covering. The actual study of the point in question shows that the abovementioned earlier works have failed to fix the relief picture of the gastro-intestinal tract with sufficient accuracy, a fact, which justifies its renewed treatment.

In the present work we do not propose to consider the relief problem comprehensively; we are primarily interested in the external shape of the relief elements, their number and approximate dimensions, mutual connections, positions with regard to the longitudinal axis of the intestine, etc., viz., the morphology of the relief elements. To help us to gain this knowledge is what these appended surface photos here aim at.

### TECHNIQUE.

The technique employed in this work has been carried out with a view to obtaining: (1) the clearness of the relief elements, (2) their actual form and position, and (3) their sufficient visibility and fitness for microphotography.

The relief is concealed primarily by the mucus covering the mucous membrane of the stomach and intestine; its amount and viscosity vary even in the same species. In very rare cases one finds in the horse, carnivora and ruminants the mucous membrane almost free of mucus. For the most part, particularly in the pig, its removal is indispensable if we want to have a clear relief picture. Formerly attempts were made at a removal of the mucus from the intact surface of the intestine, viz., the epithelium, by employing a soft brush, a faint jet of water, or by rinsing it in water, or a saline solution, or a mucus liquefying solution (e. g.

carbonate of sodium). But this way of removing the mucus proves deficient for a more thorough cleaning of the surface of the mucous membrane. As it is very difficult to carry out a removal of mucus with a simultaneous preservation of the surface epithelium, in the present work the mucus was removed mostly together with the epithelium. There being almost no difference in the thickness of the surface epithelium at the tip or edge and the base of the micro-relief elements in the stomach and intestine, its removal brings no change in the general picture of the relief, but it does so as regards the dimensions of its elements (the width of the folds or septa, the thickness of the villi, the diameter of the gastric pits, etc.). This process, easily disencumbering the relief elements of mucus, also provides us with a picture in which not only the respective relations of the relief elements, particularly in their basal parts, but also the gland openings are rendered more clearly visible. The removal of mucus in this way usually requires that the intestine shall be left in an unfixed state for several hours. Yet the space of time between the desquamation of the epithelium and the disintegration of the stroma of the relief elements is comparatively long, and in a cool place the micro-relief in the intestine of the pig, for instance, will keep for many days.

In the wall of the digestive tract, especially in that of the intestine, when it is not prevented from contracting, the relief elements get so compressed, that their basal regions and their mutual connections become concealed. To avoid this it used to be customary to fix the fragment of the intestine in a stretched out state on a cork plate. As the course of the folds in particular depends essentially on the direction of the distension, the study of the true relief picture was rendered difficult. If the stretching out happens to be working disproportionately in one direction, the circular folds may turn out to be running spirally or even parallel to the longitudinal axis of the intestine. To avoid this BUJARD's method of effecting tension has been employed here, namely by filling the tied up stomach or intestine.

To attain a better visibility of the relief or a more pronounced photograph, the fragments of the digestive tract have been kept (from a few minutes to several days) in a 2—3 per cent. solution of chromic acid to which some acetic acid has been added to prevent shrinkage.

The actual preparation of the stomach or intestine under investigation was carried out in the following way. From the intestine the mesentery was removed and its length was measured. Then from the small intestine five segments c. 15—20 cm. long were cut out and filled with either tap water or weak (0,5 per cent.) formalin solution to distend their walls, and were placed, after being duly marked, for some hours in a c. 1 per cent. formalin solution. The first of the segments was taken from the initial part of the small intestine, which still remained connected with the pyloric part of the stomach, the third segment was from the middle of the small intestine and the fifth or the last one from the end of the ileum. The first and the second halves of the intestine were again halved by segments 2 and 4. Thus, if the small intestine measured 20 metres, every part taken for investigation was 5 metres away from the next. Along with the distended parts of the small intestine, in the pig and sheep also the segments which had been allowed to contract freely were submitted to investigation. The intestine of the sheep was filled without any pressure, that of the pig and the ox under a slight pressure which caused the macroscopic folds or the sub-mucosa relief to disappear, and that of the dog, cat and horse under hard pressure (100—150 mm. Hg). The preparation of the large intestine was carried out in a similar way. The number of the segments taken from it depended on the difference in the diameter of the various parts of the intestine, ranging from 3 in the cat to 10 in the ox. From the distended or undistended gastric wall ribbons along the great and small curvature, extending from the cardia or plicated border up to the pyloric orifice were cut out for investigation.

The sections of the intestine, which had remained filled for some time, were opened lengthwise and then the mucus together with the surface epithelium was removed by a comparatively strong jet of water, whilst the relief picture that was being disclosed was from time to time controlled by the microscope. For immediate examination the preparation can be stained for a very short time (few minutes) by 0,25 per cent. safranin. If the preparations are to be preserved or photographed it is more appropriate to keep parts of them fixed on the cork plates for some time in the abovementioned solution of chromic acid; the relief elements will stiffen here and their colour turns yellowish,

a tone, which is particularly suitable for fixing their picture photographically. The fragments should be placed in the solution of chromic acid with the free surface of the mucosa upwards. For a more suitable preservation of the fragments they can be fastened with a gelatine solution to a roughened glass and then kept in a glass jar filled with c. 2—5 per cent. formalin solution. To prevent the surface of the intestine from getting pressed, pieces of paraffin of suitable height should be fastened to the ends of the glass plates. The investigation of the relief picture is carried out in distilled water by a binocular microscope.

For easier comparison of the relief pictures from various parts of the gastro-intestinal tract and particularly for fixing the number of the relief elements, the more typical areas of most of the examined fragments have been photographed. Mostly a twentyfold magnification proved to be most suitable, because it enabled us to demonstrate quite clearly the relief elements from a relatively large area of the mucous membrane.

When the relief elements were counted in the photos, each gland opening, gastric foveola, or villus was dotted with ink. Only the number of villi in the small intestine was mostly fixed on the camera glass, where every villus was again dotted with ink to avoid any repetition in counting. The area (10 sq. mm.) in which the villi were to be fixed was marked off beforehand with pencil lines on the camera glass (the surface in question when enlarged 20 times equals on the glass  $5 \times 8 \text{ cm} = 40 \text{ sq. cm.}$ ). Of course villi could be counted only in the areas where they stood regularly upright. In the case of young animals (kittens), whose villi have a different length and thickness, the number of the villi can be fixed if we remove their tips by a strong jet of water or in some other way. In most cases the villi were counted both on the mesenteric and the antimesenteric part of the intestinal wall. The material for the examination came from 3 to 10 representatives of each species.

## THE STOMACH.

The infundibular or cylindrical depressions — the gastric foveolae with the openings of gastric glands in their bottoms and the interfoveolar septa or ridges are the micro-relief elements occurring in every part of the glandular

stomach. The interfoveolar septa grow thicker in the pyloric region where their protruding free edges become partly convoluted in the contracted stomach; they assume an appearance suggestive of the cerebral gyri or even resemble the low and stocky villi. Along with these conical elevations formed by the interfoveolar septa, the real villi gastrici which do not disappear through distension of the gastric wall occur in some species; they arise from the free edge of the septa.

Before we begin to describe the just mentioned gastric micro-relief elements, attention should be drawn to the notable alterability of their shape and dimensions dependent on the degree of contraction of the stomach. Thus a shortening of the glands, their lesser density, and a complete disappearance of the foveolae in the stomach of the dog, when closely filled with food, is described by HEIDERICH (1911). In his opinion the walls of the foveolae provide the reserve which helps to form the inner surface of the stomach in the case of considerable distension. JOHNSON (1913) states that a similar extensibility of the mucous membrane takes place in the stomach of the pig and cat, and GRETVE (1936) demonstrates a corresponding disclosure by two photomicrographs, representing sections of the mucous membrane from the stomachs of two cats, one empty and the other filled with food; the extended mucous membrane here proves to be about three times thinner, the density of the glands lesser and the foveolae gastricae almost gone, so that the gastric glands seem to open directly into the gastric lumen.

Our observations prove the truth of the just mentioned disclosure with the addition that the dimensions and, to a certain extent, the shape of the interfoveolar septa depend similarly on the degree of the distension of the mucous membrane. There are certain facts indicating that the micro-relief picture can be influenced not only by the distension or contraction of the gastric wall, but also by the changes of the turgidity of the mucous membrane; however, this fact can be fixed only by direct investigation in a living animal.

In view of all this there is no reason to doubt that the micro-relief elements of the stomach are preformed structures, which though they disappear under a possible great tension, reappear in the same place, in the same mutual connections, and in the former shape and dimensions when the tension has abated.

Now let us examine the micro-relief of the stomach of the domestic mammals, which up to now has been characterized in literature only in general remarks.

Taking into account a certain similarity in the micro-relief of the stomach common to species, we may examine the domestic mammals in three groups: (1) the carnivora, the dog and cat, (2) the pig and horse, and (3) the ruminants, the sheep and ox.

Of these the first group is characterized by comparatively large foveolae gastricae and an almost complete absence of the typical villi gastrici. The second group is characterized by the occurrence of the gastric villi, particularly in the pyloric part, and the third group differs from both the preceding ones by gastric pits of a very small diameter and a great density; unlike the second group, the villi gastrici are completely absent here.

**THE DOG AND CAT.** The micro-relief elements, the foveolae gastricae and the interfoveolar septa differ in the cardiac and the pyloric parts both in the contracted and the distended stomach; therefore we have to examine the relief picture in the just mentioned parts of the stomach here, as in other animals, separately.

The micro-relief of the surface of the stomach divested of the epithelium is, in the distended state, in the dog and cat to a great extent similar. When slightly distended the micro-relief of the cardiac and fundic regions resembles a honeycomb, the diameter of whose cells and the thickness of whose walls varies considerably. In a comparatively strongly distended stomach the interfoveolar septa nearly disappear, the foveolae become less closely dispersed, and the bottom of the pits together with the gland openings becomes visible. Under maximum tension only the sites of the foveolae in the shape of groups of gland openings remain fixed.

In the distended stomach the gastric pits when viewed from above look round or oval. Their respective sizes depend on the number of gland openings into them: the foveolae into which more glands open are larger than the pits with fewer glands. The commonest number of gland openings in the bottom of a foveola is 3—5 in the dog and cat (table I, fig. 2). Seldom are there more than 6 gland openings. In the region of a single foveola

the gland openings again group themselves, mostly by twos, being separated from other similar groups by a somewhat thicker partition. Presumably such groups of glands are to be regarded as isogenic, originating from a single stem gland. In many cases the septa between such groups are so prominent that it is difficult to decide whether the glands separated by them belong to a single or two foveolae.

The diameter of the foveolae varies with the degree of distension of the gastric wall, but to a lesser extent than the thickness of the interfoveolar septa. Under a slighter tension, which destroys only the macroscopic folds, the diameter of the majority of foveolae varies between 50 and 100  $\mu$ . The shape of the foveolae, owing to a diameter of more or less the same size both at the top and the bottom of the foveola, is cylindrical. The extent of variation in the thickness of the interfoveolar septa is much greater; when divested of the epithelium they measure in a freely contracted stomach in the part under consideration under 10  $\mu$  but in a strongly distended stomach their thickness almost equals the diameter of the foveolae (table 1, fig. 2). The depth of the foveolae, which in a contracted stomach reaches 200  $\mu$ , or even more, diminishes in accordance with the distension of the gastric wall. As stated above, under maximum distension the foveolae almost completely flatten in the cardiac half of the stomach.

The micro-relief of the epithelium-covered gastric surface in the contracted stomach is rather vague, particularly in the dog. The foveolae here mostly take a slit-like shape, and, owing to frequent confluence with the neighbouring pits, their number seems to be much reduced. Similarly the course of the interfoveolar septa becomes irregular, more or less convoluted, resembling to a certain degree the cerebral gyri (table II, figs. 2 & 3); their thickness is quite uniform, varying mostly between 40 and 60  $\mu$ . Unlike the relief of the pyloric region, not all the foveolae are concealed here by interfoveolar ridges, but some of them at least escape confluence. In the cat the confluence of the adjacent foveolae in the contracted gastric body (*corpus ventriculi*) occurs less frequently than in the dog; the interfoveolar septa here form a more or less even surface in which the foveolae appear in the shape of slit-like or irregularly angular punctures (table II, fig. 3). The pseudovillous surface-relief, which is sometimes noticeable in the pylorus, does not occur here.

We find a somewhat different micro-relief picture in the pyloric part of the stomach (*antrum* and *canalis pyloricus*). The difference becomes most distinctly apparent in the relief of either region of the stomach fixed under considerable distension. According to the micro-relief elements which occur or become apparent in either region we may call the corpus part an area of gastric foveolae, and the pyloric part of the stomach an area of interfoveolar ridges, since in the latter region the individual depressions are usually concealed by protruding ridges. The septa here are usually more convoluted and their thickness is a little greater (c.  $75 \mu$ ) than in the corpus. In some places or in the stomachs of some animals the interfoveolar ridges seemingly lose their continuity, emerging on the surface surrounded on all sides by slit-like depressions. Such derivatives of the septa are suggestive of low stocky villi. In this case the micro-relief picture appears granular (table II, fig. 7). A typically granular or pseudovillous relief picture is not to be found in every dog (depending possibly upon the degree of the turgidity of the mucosa), and in the cat it seems to be exceptional.

Only under a stronger distension of the gastric wall are the slits between the ridges replaced by foveolae and the flexuous course of the septa becomes straightened (table I, fig. 3 and table II, fig. 6). Here the foveolae have a diameter twice as long as in the corpus, and their depth is also much greater; this is particularly true in the dog, a fact, which renders the demonstration of the gland openings difficult here. In the cat the number of gland openings seems to vary here more than in the corpus region; up to 10 glands open here into a single foveola. The distension of the stomach is accompanied by the flattening of the free edges of the interfoveolar septa. In some animals or in certain parts of the stomach such a flattening is complete, elsewhere even under a considerable tension a few broadbased flat and low elevations remain at the point of the intersection of the septa, suggesting rudimentary villi. Their occurrence is not characteristic of all individuals, and, even if they occur, they disappear completely under a very strong distension, so that we cannot regard them as typical gastric villi; the term pseudovilli might be applied to them. Owing to their partial occurrence and the possibility of their disappearance we must regard them as functional, i. e. structures dependent on a certain degree of the contraction of the gastric

wall and possibly on the extent of the turgidity of the mucous membrane.

The transition of either class of relief into the other proceeds gradually with the boundary line in question lying mostly in the region of the gastric body. It is worth noting that the differing relief areas almost never fully coincide with the regions of the fundic and pyloric glands, or that the boundary line between different relief regions does not coincide with the boundary line between different gastric glands. The latter, as shown in a work done in this institution by KASK (1938), lies much nearer to the pyloric orifice than the boundary line of the relief types, approximately between the antrum pyloricum and the canalis pyloricus. Consequently the micro-relief picture is not suitable for fixing the extent of the fundic and pyloric gland regions.

In the freely contracted stomachs of the cat and dog the number of the gastric pits in 1 sq. mm. varies between 60 and 90 in the corpus region, being reduced twice as much or more in the pyloric part. The total number of the gastric pits extends in the dog (German shepherd, c. 8 months old) to a little over a million (1 266 000).

**THE PIG AND THE HORSE.** The micro-relief of these animals has a greater resemblance to that of the dog and cat than to that of the ruminants; with the former they have in common polyglandular foveolae, but the real gastric villi, characteristic only of the pig and horse, constitute the distinguishing feature between these two groups of animals. From the ruminants they differ in the polyglandularity of their foveolae as well as in the just mentioned occurrence of villi.

In the epithelium-covered and freely contracted stomach of the horse foveolae in the fundic region occur mostly as confluating fissures, but in the pyloric part of the stomach they are completely concealed or replaced by depressions which surround the villi occurring here (table II, fig. 8). Interfoveolar or interfissural structures appear in the fundic part in form of convoluted ridges, the free edges of the interfoveolar septa reaching the surface, and in the pyloric part as gastric villi rising from the edges of the interfoveolar septa. In a freely contracted stomach these processes lend a granular appearance to the surface of the mucous membrane of the pyloric region. The villi gastrici appear here as rounded, oval or ovoid structures, resembling grains of

rice with a varying diameter of about 100  $\mu$ . The transition of either type of relief into the other is gradual, taking place in the small curvature in close vicinity to the plicated border and farther off in the large curvature. Here, as in the cat and dog, the vague boundary line of the relief types in question does not fully correspond to that between the fundic and pyloric glands.

A clearer character of the foveolae and the interfoveolar septa is revealed by the epithelium-freed and distended preparations which show that the foveolae in the fundic part are lower and of a less uniform size than those of the pyloric region. On the surface they generally appear irregular in shape, especially in the fundic region, and the larger are further subdivided by lower ridges. This last fact renders it difficult to fix their exact number. The number of gland openings in their bottoms is also highly variable, ranging from a few to over 10 in the long furrow-shaped foveolae. In the pyloric region the foveolae are so deep that their bottoms can hardly be seen from the surface; their shape is tubular. The free edges of the interfoveolar septa here form a base for the mostly tongue-shaped, short (100—200  $\mu$ ) villi.

The micro-relief of the stomach of the pig differs most essentially from that of the horse in its regular, more or less round shape and the rather uniform diameter (of about 100  $\mu$ ) of the foveolae in the cardiac part of the stomach. By contrast with those of the horse and carnivora the foveolae of the pig in the region mentioned remain open (not compressed into a slit-like shape), and therefore clearly separated from one another even in a freely contracted stomach. The micro-relief of the epithelium-freed stomach of the pig in its cardiac part seems to resemble in its regularity the honeycomb more than is the case with any other domestic mammal. The number of foveolae in 1 sq. mm. of an undistended surface mostly amounts to 75—100. The usual number of gland openings in their bottoms is 2—4.

Between the cardiac relief region with very uniform foveolae and the pyloric part of the stomach, where the gastric villi occur, there is in the pig a large intermediate area characterized by a different relief picture. This region, very broad in the great curvature, gradually narrows toward the small curvature of the stomach, where it disappears. The epithelium-freed sur-

face of this region is represented on table II by fig. 5, which is a photograph made from an undistended specimen. As one may see, the foveolae here are very irregular in shape and size, containing from 1 up to 5 or more gland openings in their bottoms. They are separated from one another by very low ridges of variable thickness; a part of them does not anastomose completely with the others, thus rendering the separation of the foveolae in many cases only partial and the fixing of the exact number of the foveolae impossible. The transition of this intermediate region is gradual in both directions.

As in the horse, here too, the interfoveolar septa of the pyloric region are covered with gastric villi. For the most part the size of the tongued-shaped villi varies here more than in the horse, their diameter ranging from c. 50  $\mu$  to over 150  $\mu$ . In the contracted stomach their number in 1 sq. mm. amounts to over 100 (table I, fig. 4).

**RUMINANTS: THE OX AND THE SHEEP.** On the ground of the abomasal microrelief the ox and the sheep differ most characteristically from the above described domestic mammals. Owing to their very small diameter the foveolae from the undistended spiral fold appear in a microphotograph, prepared under twentyfold magnification, as very closely scattered dots (table II, fig. 4); their closer characterization is possible only under a stronger magnification. If viewed from above, the foveolae here look round, in the adult animals separated by a uniform distance from one another. In the younger animals (sheep under 1 year) double foveolae, with their contiguous flat sides separated by a thin septum, are to be found in varying numbers. Isogenic groups, consisting of a greater number of foveolae, seem to be absent. The diameter of the epithelium-freed foveolae varies in the region of the spiral folds from 20 to 30  $\mu$  in the sheep and from 30 to 50  $\mu$  in the ox, equalling approximately the thickness of the epithelium-freed interfoveolar septa. The foveolae of the sheep are thus considerably smaller than those of the ox. As the ensuing data show the density of the foveolae also differs considerably in these animals, being greater in the sheep.

Unlike other animals, there is no noticeable change in the relief pictures of the pyloric region of the abomasum, except the increased diameter of the foveolae and their lesser density in the sheep, especially on the sides of the gastric areas.

## Density of gastric pits in ruminants.

Species	Part of abomasum	Area from which the number of foveolae has been estimated	Number of foveolae in 1 sq. mm.	Remarks
Sheep, male, 10-12 months old . . . . .	Cardiac part of the spiral fold	0,7 mm <sup>2</sup>	640	Mucous membrane undistended
Sheep, male, adult		0,7 mm <sup>2</sup>	670	
Ox, female, calved 7 times . . . . .		10 mm <sup>2</sup>	145	
Ox, female, calved 9 times . . . . .		10 mm <sup>2</sup>	203	
Ox, female, calved 7 times . . . . .	Pyloric part of the abomasum	5 mm <sup>2</sup>	240	Mucous membrane moderately distended
Ox, female, calved 9 times . . . . .		10 mm <sup>2</sup>	152	

According to ELLENBERGER's (1911) data (p. 239) the inner surface of the abomasum in the ox equals c. 6240 sq. cm. and in the sheep 2000 sq. cm. If the average number of the foveolae in 1 sq. mm. of the whole gastric mucosa is taken as 175 in the ox and 600 in the sheep (a decline of their density in the pyloric part is taken into account in this animal) the total number of foveolae seems to be about equal in the abomasum of the ox and sheep, amounting to 110 millions in the ox and 120 millions in the sheep.

The depth of the foveolae cannot be fixed from a surface view, the more so because we cannot speak of the bottom of the foveolae as the level at which the gastric glands open. As a matter of fact, in ruminants we can speak of the gastric foveolae only comparatively; their real shape and relation to the gastric glands scarcely justifies it. As most of the foveolae here and particularly in the region of pyloric glands are associated with only one gland, whose diameter does not differ essentially from that of a tubular gastric foveola, it would be more appropriate to speak with reference to the sheep and ox of gland ducts instead of foveolae.

This conception is also justified by the examination of the microscopical sections. In the fundic region, for instance, the body of the gland is followed by a slightly wider gland duct, whose epithelium contains in the ox for the length of about 150—

200  $\mu$  numerous mitotic figures and some parietal cells which are characteristic of the neck part of the fundic glands in other animals. Both the mitotic figures and the parietal cells disappear only in the closest proximity to the gastric surface. The bifurcation of the gastric glands, which seems to occur oftener in the fundic region than in the pyloric part, usually takes place at the level between the gland body and its duct, or neck part, and only seldom in the close vicinity of the gastric surface. Accordingly most of the gastric glands in ruminants have their own gland ducts, a smaller number of them opens into a common duct by twos, and still more exceptional is the branching of the gland duct itself. Therefore it is impossible in ruminants to speak of the bottom of the foveolae or of a clearly defined boundary line between the foveolae and the gland ducts. With the foveolae are comparable only the upper parts of gland ducts, measuring about 100  $\mu$  in length; their epithelium is devoid of mitotic figures and those of their cells which are turning cylindrical carry supranuclear lighter parts.

This disclosure renders ELLENBERGER's (1911) controversial generalization, according to which at least 8 to 16 glands open into every gastric pit, as well as SAPPEY's (1894) schematic figures representing four fundic and four pyloric glands as opening into a single foveola of the ox incredible. Surely the pictures represented in SAPPEY's illustrations are to be regarded as exceptional and ELLENBERGER's assertion is invalid with regard to the ox and sheep. Besides, in the illustrations of ELLENBERGER's own work representing the gastric glands of domestic ruminants the branchings of the fundic or pyloric glands or of their ducts (fig. 233 excepted) are completely missing.

The interfoveolar surface of the stomach is smooth in the ox over all its extent, and in the sheep at least over the region of the spiral folds. Only in the pyloric part of the sheep, and exceptionally of the ox, can we find the interfoveolar septa ridge-shaped, overreaching the foveolar openings (table II, fig. 9). By distending the mucous membrane they also get smoothed down. We have not observed in our material from either animal the villiform structures mentioned by ROLLET (1871) and ELLENBERGER (1911) as occurring in the pyloric region of the abomasum of the ox.

## THE SMALL INTESTINE.

The microscopical elevations in the small intestine of domestic mammals are of different kinds. Generally one can distinguish here between net-arranged or parallel running folds, occurring most characteristically in domestic ruminants, or lamellar structures of various types, peculiar to the pig and, lastly, the round cylindrical villi, covering the inner surface of the whole small intestine in the horse and domestic carnivora.

Their shape and dimensions are here also greatly variable, depending not only upon the degree of distension of the intestinal wall, but also upon the state of contraction of their own musculature. The numerical data, illustrating their dimensions, should therefore be regarded as only approximate.

**THE SHEEP.** The micro-relief of the small intestine of the sheep is not uniform over all its length, likewise the relief picture varies to a certain extent individually in the corresponding parts of the intestine. It is most constant or subjected to fewest individual variations in the duodenum and ileum; at the same time the micro-relief of the initial and end parts of the small intestine differ from each other to a greater extent than the relief pictures of the intervening segments between themselves.

Owing to essential differences in the investigated sections of the intestine, we are going to describe them separately.

In the initial part of the duodenum the free surface of the mucous membrane is covered with reticularly connected folds free from villi; the direction of the folds with regard to the longitudinal axis of the intestine is irregular. On the level of the pyloric orifice there is a narrow transitional zone, whose micro-relief is formed by a very delicate reticulum with irregular meshes resembling the gastric pits (table III, fig. 1, upper part of the illustration). A few cm. further the folds grow thicker and the meshes become wider, being partly divided by lower folds into still smaller chambers in which from 1 to 10 gland openings are located (table III, fig. 2). The sharpening free edge of the folds has a wavy outline, but the villiform elevations are generally missing in a distended duodenum. Still further away from the pylorus the secondary folds disappear in the bottom of the meshes, so that the latter become more or less even

(table III, fig. 4). The direction of the folds is not orientated here and their height varies even within the limits of a single mesh. Generally the folds bounding the meshes lengthwise are higher and of a more uniform height than the folds bounding the meshes at the ends. As in many places the folds come to an end becoming gradually lower without being joined to their neighbours, the meshes between them are often partly united with one another (table III, fig. 4). One can find only occasionally in the duodenum completely isolated parts of folds, resembling tongue-shaped or low cylindrical villi. The thickness of the folds and the diameter of their meshes varies noticeably according to the degree of the distension of the intestinal wall (compare figs. 3 & 4 in table III), and their height in the fixed preparations does not greatly exceed 200  $\mu$ . The location of the gland openings at the bottom of the meshes is irregular in contrast with the posterior segments, where they are generally placed in a single row between the adjacent folds. Individual differences in the micro-relief of the initial part of the duodenum are not very essential.

At the beginning of the second quarter of the small intestine (segment 2) the relief picture is less uniform. Here again we find the folds but unlike those from the duodenum they possess a dentated free edge, resembling to a certain degree a blunt-toothed saw. The individual projections have a varying height and shape, but, as a rule, these broad-based leaf-like structures, standing at varying intervals from each other, are less high than the underlying folds. The relief picture here is further diversified by the degree of the mutual connection of the plate-like folds. In some animals, here too, the folds are reticularly connected, in which case their course is irregular (table III, fig. 5). In other cases we see the reticulum replaced by transversal or circular running folds of greatly variable length (up to 2 mm. or even more). They are partly furnished with crosswise running lower prolongations, which, springing from the circular ones and becoming gradually lower, come to an end, or entering into connection with adjacent circular folds enclose the transversally-oblong meshes. Between the circular folds the gland openings are mostly situated in a single row; if the folds are connected reticularly, this regular arrangement of the gland openings disappears.

In the middle of the small intestine (initial part of the third quarter, or segment 3) the relief picture also varies individually. As a rule, we find here thin, plate-like parallel folds, running transversally; from their free edge comparatively high (up to  $400 \mu$ ) broad-based leaf-like villi with rounded edges or sharp tips emerge. The folds themselves become lower ( $50$ — $100 \mu$ ) than in the cranial segments (table IV, figs. 1 & 2), and their variable length sometimes reaches over 5 mm. The transversal anastomoses between the circular folds are mostly lacking. The broader of the villi are bifurcated.

Quite a different picture was found in two out of six investigated sheep in the intestinal segment just under consideration. The fold-like elevations were wholly absent here, being replaced by low conical villi, originating separately from the surface of the propria.

The greatest individual variability of the relief picture is found in the initial part of the fourth quarter of the small intestine. One can find here low conical or broad-based leaf-like villi arising independently from the intestinal surface (table IV, fig. 3), secondly short circular folds covered with low villi, and thirdly low reticularly arranged folds possessing no villi (table IV, fig. 4). A difference in the age of the animals probably does not solely account for these variations.

The inner surface of the ileum, i. e. of the final part of the small intestine, is covered with circular short plate-like folds between which the cross anastomoses are nearly always lacking, and from whose wavy free edges sometimes one or several low leaf-like villi take their origin. In some preparations, besides the short folds, low conical or tongue-shaped single villi occur in varying numbers (plate IV, fig. 5). Here, as in other parts of the intestine, the straightened course of the folds gets lost in the freely contracted fragments.

The relief picture exhibited here necessarily differs from that represented in earlier descriptions because those, with few exceptions, have not taken into account the possible variations peculiar to the various subdivisions of the small intestine. Thus according to SCHRIEVER (1899) villi-like structures are wholly lacking in the intestine of the sheep, being replaced by reticular ridges (Kämme), which should produce a relief picture resembling the reticulum of the ox. MARTIN's (1906) description, compris-

ing only a few lines, runs as follows: „Beim Schafe sind die Zotten kurz, breit und plump, in den meisten Fällen nur als Fältchen erhobene Zotten, oben meist mehr oder weniger stumpf-rund.“ Though he states that his characterization coincides with that of SCHRIEVER (1899), yet only the occurrence of villi is mentioned here. According to MATTHIAS (1910) the intestinal micro-relief of the sheep is formed by reticularly connected ledges (Leisten), whose edges owing to indentations resemble the tips of the villi (p. 19). BUJARD (1909) in his description identifies the relief elements of the sheep's intestine as lamellae, ridges (crêtes) and lined up filiform villi (villosités filiformes en séries). VAU (1932) has been trying to correct the earlier data in literature by examining as many intestinal segments as possible, but he has met with an insurmountable difficulty in the removal of the mucous layer; therefore he describes only the upper parts of the relief elements protruding out of the mucus.

From what has been said it is obvious that the inadequacy of the earlier data in literature has been occasioned primarily by the deficiency of the research technique. Actually the micro-relief of the small intestine varies considerably in the gastrocaecal direction, and when investigating only a certain part of it we are liable to go wrong if we attribute the disclosed picture to the whole of the small intestine. Besides, as we have seen, in the sheep the individual differences in the corresponding intestinal sections are quite considerable.

In MÖLLENDORFF'S manual of human micro-anatomy, vol. V, part 3, PATZELT (1936) characterizes the relief of the small intestine in the sheep and other domestic mammals on the ground of the data provided by SCHRIEVER (1899) and MARTIN (1906).

**THE OX.** In the ox the micro-relief of the small intestine is of all the other domestic mammals nearest to the sheep, but yet, as the ensuing description will show, it differs from it in many respects.

As in the sheep, here too, the relief picture varies considerably in different sections of the intestine and also individually. In the ox the intestinal micro-relief is composed of folds of variable length, position and reciprocal connection, and villi-like projections of varying shape and dimensions arising mostly from the free edges of the folds.

The initial part of the small intestine is characterized by folds of varying height and thickness, the run of which is generally curved. The round, oval or irregular eyes closed in by the folds are of greatly varying size. The relief picture characteristic of this region is represented by table V, fig. 1. The folds in the epithelium-freed preparations have a sharpening wavy free edge which in some places appears irregularly dentated. The narrow-based villous structures seldom occur here. Amongst the less densely lying folds we often find places where the rounded or oblong groups of closely anastomizing folds are separated from one another by comparatively wide (up to 500  $\mu$ ), flat-bottomed furrows (table V, fig. 1). The latter are pierced through by many rows of gland openings, but in the very vicinity of the pyloric orifice such furrows may be devoid of glands, a picture, characteristic also of the sheep (table III, fig. 1). Frequently such flexuous furrows anastomose, dividing the areas covered with folds into smaller fields of varying extent. In the above mentioned densely anastomizing groups of folds eyes of varying sizes, with one or many propria glands opening into them, resemble to a certain degree the gastric foveolae. In the case of uniglandular eyes the gland seems to be opening into the ridge of the fold. In the immediate vicinity of the pyloric orifice the folds become thinner and lower and their connections closer.

The relief picture described is peculiar solely to the initial part of the small intestine and does not recur in any posterior section of the intestine investigated. Yet it does not seem to coincide in area with the region of the duodenal glands, for the relief picture described is superseded by a different one a few centimetres away from the pyloric orifice, a relief that is peculiar to the initial portion of the second quarter of the small intestine.

The micro-relief of the initial part of the second quarter of the small intestine has no such peculiar character by which the just mentioned section of the intestine could be distinguished from other subdivisions of the small intestine, except the initial part of the duodenum and the ileum. Only its picture is more constant than that of the beginning of the third or fourth quarter of the intestine.

Here again the relief elements are represented by folds whose free edge is serrated and which by contrast with the initial part

of the duodenum have a more or less straight course, the longer of them being situated transversally. The eyes between the folds are angular in distended preparations and the longer of these are situated transversally with the longitudinal axis of the intestine. The gland openings in the bottom of the eyes or meshes lie in one or two rows (table V, fig. 2). A certain regionality, displayed in the run of the folds and their mutual anastomoses, is a common feature here. Beside the regions, whose relief is mainly formed of the folds running transversally and furnished with free ending or anastomizing branches, there are areas in which the run of the folds is less orientated, sometimes zig-zag, with the eyes between them smaller owing to more frequent anastomoses. This difference does not seem to depend on the occurrence of lymph follicles, for both areas, when transilluminated, appear equally translucent. The tongue-shaped or low conical solitary villi, arising directly from the surface of the propria are seldom to be found here.

In the middle of the small intestine again folds are the micro-relief elements, but their anastomoses here are casual. The greater part of the folds in almost all the animals investigated (10) is separate here. The length of the folds varies everywhere, from very short ones resembling tongue-shaped solitary villi or lamellae to longer ones measuring over 5 mm. As a rule the longer folds are situated transversally and the shorter ones mostly have a longitudinally directed base. Owing to the partial connections of the folds many of them appear bifurcated (table V, fig. 3). The wavy or low-toothed free edge of the folds is only exceptionally covered with clearly separated villi, in which case the picture rather resembles that of the sheep (table IV, fig. 2). In the ox the elevations of the free edges of the folds are generally low, seldom rising in a slightly distended wall of the intestine to the height of the fold itself. The gland openings between two adjacent folds are in one or two rows.

The micro-relief picture of the initial part of the fourth quarter of the small intestine varies individually more than that of the cranial sections, being at the same time more closely related to the relief of the second quarter. By comparison with the middle part of the intestine the anastomoses of the folds occur oftener here, presenting for the most part the picture shown in fig. 4 table V.

The final part of the small intestine is charac-

terized by parallel folds running circularly, covered with conical villi (table V, fig. 5), or having only a wavy free edge (table V, fig. 6), and by tongue-shaped or conical solitary villi arising directly from the surface of the propria. Commonly only one of the just mentioned relief variations is to be found in the same animal. The longitudinally arranged short folds or lamellae connecting the circular ones are almost completely absent here. The distance between the adjacent folds is the same as in the preceding sections. The villi arising directly from the propria seem regularly to be separated from their neighbours by a single row of gland openings (with about 3—5 gland openings for every villus).

If we compare the description presented here with the data in the literature relating to this matter we are here, as in the case of the sheep, inevitably faced with discrepancies. Thus SCHRIEVER (1899), HILTON (1902), MARTIN (1906) and MATTHIAS (1910) characterize the micro-relief elements of the small intestine in the ox as villi, which according to SCHRIEVER's assertion are "more slender and longer than in the horse". At the same time the abovementioned authors provide us with numerical data concerning the dimensions and the number of villi. One is led here to the conclusion that these authors have described only parts of the relief elements protruding from the layer of mucus. The most appropriate identification of the relief elements under consideration is given by BUJARD (1909), which, though in general terms, has fixed the variations of the relief picture in the main subdivisions (duodenum, middle of the small intestine and ileum) of the intestine.

THE MICRO-RELIEF OF THE SMALL INTESTINE IN THE SHEEP AND THE OX IN GENERAL. Having regard to the zoological relationship and to the resemblance in nutrition of the species under observation, the far-reaching similarity in the micro-relief of their small intestine is to be regarded as natural. In both species the fundamental forms of the micro-relief elements are the reticularly arranged folds; the cross anastomosis between them partly disappears in the middle of the small intestine and almost completely in the ileum. The breaking up of this network is primarily brought about by a partial or complete reduction of the longitudinally running folds, but it is completed to a certain extent also by a partial retrogression of the circular folds, especially in the middle of the intestine and in the ileum. At the

beginning of the fourth quarter of the small intestine, at least in some individuals, the anastomoses become again more frequent, but in the ileum the reticulation of the folds is completely absent. The longitudinal folds have disappeared here almost without exception, and to a very varying extent reduction has also affected the circular folds; thus here, in the sheep as well as in the ox, we find in one individual circular folds with a wavy free edge, in another circular folds covered with leaf-like or sharp conical villi, and finally in a third separate leaf-like or conical villi.

The abundance of villi and their development seems to be in a certain reciprocal relation with the degree of the retrogression of the reticulation of the folds: in the initial part of the intestine, that is, in the region of the reticularly arranged folds we mostly find only a few low villi arising from the free edge of the folds; their highest degree of development is attained in the middle of the small intestine, particularly so in the sheep (table IV, figs. 1 and 2) and in the ileum. No part of the small intestine is characterized by a complete absence of villiform projections. Owing to the differing shape and dimensions of the villi and, on the other hand, to their almost unexceptional connection with the folds, it is impossible to fix their exact number, or this may be conceivable only in the ileum of such individuals whose villi are regularly separated from one another.

The villi of the ruminants are predominantly leaf- or tongue-shaped with a base running parallel to the corresponding fold. In the ox they are generally less developed than in the sheep.

The fold-relief, whose various modifications are encountered in the domestic ruminants, occurs in the mammals only as an extreme exception (according to JACOBSHAGEN, 1937), in the mole and some insectivorous chiropters. On the contrary, the fold-relief is very common in amammalia, where the relief picture also often varies in the subdivisions of the intestine.

The gradual change in the relief picture of the ruminants, revealed in the reappearance of the net-arranged folds at the beginning of the fourth quarter of the intestine, after they have been replaced by the parallel running solitary folds already in the middle part of the intestine is interesting and demands further elucidation. If these conditions were confirmed on more comprehensive material, this phenomenon would serve as a valuable addition to the elucidation of the evolutionary mechanism of the

relief forms; in any case the intestine of the ruminants seems to be a very appropriate object for that purpose, for the development of the relief elements proceeds here quite differently from that of other animals: the folds, occurring in the early embryonic stage, are later replaced throughout the whole extent of the small intestine by finger-shaped villi, which in their turn are postnatally again replaced by the fold-relief.

The areolar variations of the relief picture which occur to a certain extent in all the described subdivisions of the intestine are notable in the intestines of the ruminants. Generally the relief is greatly modified at the level of solitary or aggregated lymph nodules, but we are not concerned with these differences in the present paper. Along with it the areolar variations of the relief occur also in places where the structure of the propria appears to be uniform, judging by the transillumination of the intestinal wall. Such a variation cannot be explained by its areolar relation to the mesentery, nor can it be explained by the differences in the degree of distension in the wall of the intestine; it might rather be regarded as corresponding to the relations in which such different areas stand to the macroscopic folds of the Kerckring relief. But in such an assumption a preformation of the Kerckring relief is implied, an implication which is not borne out by the results of various investigations (GRETTEVE, 1936).

**THE PIG.** The material of the pig we had at our disposal came mostly from animals of bacon age (79 kg. and upwards). Yet, taking into consideration the general similarity of the relief picture between the younger and older animals investigated, it may be inferred that the relief form found here coincides with that of adult animals, or, what is the same, that its evolution is completed already during the earliest postnatal months.

Generally the micro-relief of the pig's intestine is subject to greater variations, both individually and in the subdivisions of the intestine, than in any other of the domestic mammals investigated.

The micro-relief is composed here of sharp-edged, plate-like or lamellar folds of varying length, run and mutual connection. The similarity between the relief pictures from the intermediate segments (2, 3 and 4) of the intestine is greater than that between them and the micro-relief of either the duodenum or the ileum. The widest difference is revealed by the comparison of the duodenum

with the ileum; the relief picture is most complicated in the former, and most regular and simple in the ileum. The simplification of their shape and the straightening of their course toward the sharp, wavy free edge is characteristic of the relief elements just mentioned. In the basal parts of the folds their shape becomes greatly irregular owing to a varying number of thin triangular side-plates attached to the main lamella transversally. In the initial part of the small intestine these side-plates attain the highest degree of development, but in the ileum they are almost completely missing (table VI, fig. 5). The conical or cylindrical villi, arising independently from the surface of the propria, are exceptional relief elements in the small intestine of the pig. The pointed tongue-shaped villi (of which we see three in fig. 2, table VI) are more frequent, and still commoner are round-edged, leaf-like lamellae, particularly in the ileum (table VI, fig. 5). The sharp, conical villiform prolongations, which take their origin from the free edge of the plate-like folds (shown in figs. 1 & 4, table VI), were represented in our material in all parts of the small intestine except the ileum only in two pigs (of 79 and 230 kg.); in the other three pigs of intermediate weight they were lacking, being replaced by a wavy or blunt-toothed, sharp, blade-like edge.

Further structures, peculiar only to the pig, though not occurring in all individuals, are the round or oval, cylindrical depressions in the folds, or more frequently in their anastomizing points with a diameter of 100—200  $\mu$ ; the gland openings at their bottom, owing to their great depth, are invisible. On removing the wall of such foveolae, we find that 3 or more propria glands open into them. At the point of those depressions the fold gets broader, resembling the picture we get if we press a round pencil into the ridge of a fold made of plasticine. Although they have a certain similarity to the meshes, bounded by the circularly anastomizing folds (ring-folds), also occurring in the pig, one can as a rule easily identify them as being mostly related to a single fold. A few less regular circularly connected folds are seen in fig. 2, table VI.

The mutual connections of the lamellar folds can be seen most markedly in the duodenum. The meshes bounded by the greater, higher and thicker folds are mostly subdivided by thinner and lower ones. Thus we may here speak of two networks, of which the one with slighter folds and lesser meshes takes a basal

position in relation to the greater lamellae. In the posterior parts of the intestine the slender basal folds are missing or are represented by slight side prolongations of the main lamellae.

The shape of the larger folds varies in the duodenum individually and in area; beside the picture presented by fig. 1 in table VI, we find elsewhere a network of folds with smooth edges, or even one with small and round eyes, resembling the picture given in table VI, fig. 6. A different relief, consisting of more closely connected thinner folds without any definite orientation, often is found on the ridges of the Kerckring folds.

The relief elements of the initial parts of the second, third and fourth quarters of the intestine consist of lamellar folds of varying length and shape, richly ramifying in their basal parts (table VI, figs. 2, 3 & 4). The picture is suggestive of a network, the partial retrogression of which has taken place not in the anastomosing points of the reticulum, as is the case with ruminants, but in the middle between the adjacent knots. Along with such sharp-edged ramifying folds, leaf-like lamellae, furnished with very delicate side projections in their basal parts, or even a regular network of folds, may be found. The degree of anastomosis varies even in one and the same fragment in area.

The most constant relief picture is found in the ileum. Outside the Peyer plates there are short folds or leaf-like lamellae with rounded edges (table VI, fig. 5). Between them anastomosis is missing almost completely, and so the side-projections have also disappeared. Their arrangement is more regularly transversal than in any cranial part of the intestine. Fig. 6 in table VI gives us the picture of an exceptional relief variety, which resembles duodenal or even pyloric relief; as it occurs only in certain areas and not in all individuals, it is not to be regarded as typical of the ileum.

Individual variations of the micro-relief are displayed by the degree of anastomosis or fragmentation of the folds, their varying thickness and the shape of the free edge. Generally there are individuals with a very pronounced reticulation of the thin folds nearly all over the small intestine except the ileum (pig, 90 kg.) and others, whose relief is made up of richly ramifying lamellae, separated from one another. Likewise the villiform projections attached to the ridges of folds or lamellae do not occur in all

individuals. To what degree the individual variations are to be regarded as racial or dependent on the nutrition or some other circumstance has not been elucidated by our material.

The gland openings are located between the folds or lamellae with apparent irregularity. Only in the duodenum do they appear exceptionally to open in the ridge of the folds. It is difficult to fix their number as they are partially concealed by the ramifying folds, even in the distended intestine.

As the above description and the appended microphotos show it is impossible to fix the number of microscopic elevations in the small intestine of the pig, except the solitary short folds or lamellae in the ileum.

The most characteristic feature in the small intestine of the pig differentiating it from the domestic ruminants (sheep, ox) is the intense ramification of the basal parts of its relief elements and the more irregular course of the latter. A greater similarity in the micro-relief of the intestine of the pig and domestic ruminants can be found in the ileum.

SCHRIEVER (1899), MARTIN (1906) and MATTHIAS (1910) characterize the micro-relief elements of the small intestine in the pig as villi united basally. Nearer to our observations comes BUJARD's (1909) characterization.

**THE HORSE, DOG AND CAT.** The horse with the domestic carnivora has a more regular micro-relief of the small intestine, than any other domestic mammal. Individual variations in the shape of relief elements in the species are scarcely perceptible as well as those in different subdivisions of the intestine. Hence the data in literature relating to this matter generally concur, agreeing at the same time with the actual picture, a fact which renders a more detailed description superfluous here.

In the species mentioned the digitiform villi occur throughout the whole extent of the small intestine (table VII, figs. 1, 2 & 3). With the exception of the initial part of the intestine they occur in a regularly cylindrical shape, and only in the duodenum, particularly in the dog (table VII, fig. 2), and in a lesser degree in the cat; we find along with them to a varying extent flattened villi arranged with their longer diameter transversally, especially, if they occur in larger numbers. In the duodenum of the cat the flattening of the villi occurs mainly in their basal parts. Generally they have a uniform length and upright position, so that they

are not partially concealed by the others as is the case with newborn kittens or other animals, where the variation in the length and diameter of the villi is very great. In adult animals the length of the villi is approximately 1 mm. in the dog and cat and 0,5 mm. in the horse (fixed material). In the subdivisions of the small intestine their length does not vary considerably, except in the initial part of the duodenum where they are shorter.

The number of villi, presented in the following table, can be fixed more objectively than their dimensions.

**Number of villi in the small intestine of the horse, dog and cat.**

Species	Total surface area of the distended small intestine in sq. cm.	Number of villi in each 10 sq. cm.	Total number of villi in the small intestine
Horse, castrated male, 14 years old . . . . .	31 600	120—210	47 400 000
Horse, female, 19 years old . . . . .	48 720	101—118	52 714 000
Dog, male, 7—9 months old <sup>1</sup> . . . . .	2 107	72—89	1 735 000
Dog, male, 14 years old <sup>2</sup>	1 100	110—125	1 276 000
Dog, male, 15 years old	1 352	111—122	1 578 000
Cat, female, 1 day old . .	69	375—466	306 000
Cat, male, 8—9 months old . . . . .	595	120—185	984 000
Cat, male, 4 years old . .	884	100—183	1 285 000

As may be seen, the number of villi is smallest in the cat (1 285 000), a little greater in the dog (1 276 000—1 735 000), and greatest in the horse (47 400 000—52 714 000). In the same species the greater number of villi corresponds to the greater intestinal surface. With regard to the subdivisions of the intestine

<sup>1</sup> The total number of propria glands, or more properly, the number of their bottoms or blind ends reaching the granular layer in the small intestine of the same individual was 25 110 000.

<sup>2</sup> The total number of the gland openings in the small intestine of the same animal was 6 655 000 and in the large intestine 2 148 000.

the density of villi varies, being in the cat and dog smallest in the duodenum and greatest in the intermediate segments of the intestine. In the new-born cat the total number of villi is about 4 times smaller than in the adult animal, but the density is greater here. The numbers of intestinal villi in the dog given by HEIDENHAIN (1888) and MALL (1888) agree with the presented data.

The gland openings are located between two adjacent villi in a single row. Their exact number can be estimated only if the villi are removed. In the dog their total number in the small intestine amounts to over 6 millions thus exceeding the number of villi fivefold, or for every villus there are 5 gland openings. Their density does not seem to differ essentially from the density of gland openings in the large intestine of the dog: in a distended small intestine there are in every 10 sq. mm. 450—665 and in the large intestine 420—670 gland openings. The number of gland openings in the small intestine of the dog does not equal the number of gland bottoms of which there are about 3—4 times as many. Thus, for instance, a 7—8 years old boxer had in a preparation from the middle of the small intestine in the same area of 10 sq. mm. 90 villi, 450 gland openings and 1100 gland bottoms. To fix the latter figure the glandular layer was separated from the rest of the intestinal wall, and the glands were photographed from such a preparation by transillumination or by reflected light. This discrepancy in the number of gland openings and gland ends, or bottoms, points to the ramification of the propria glands in the small intestine of the dog, indicating at the same time that the exact number of the propria glands cannot be fixed in microscopic sections.

### THE LARGE INTESTINE.

The micro-relief of the large intestine in all domestic mammals consists of a smooth surface diversified only by the numerous gland openings in it (table VII, fig. 5 & 6). The surface elevations, villi or anastomizing folds, peculiar to the species in prenatal life, have disappeared without trace by the time of birth or soon after it, and so has the linear arrangement of the gland openings. Similarly the number of double-openings belonging to the isogenic glands decreases gradually and becomes wholly absent in adult individuals. Fig. 5 in table VII shows some of them. In the

adult animals the gland openings are dispersed uniformly, being placed at an equal distance from one another.

The interval between the gland openings increases concurrently with the distension of the intestinal wall. On the surface of the epithelium-freed large intestine the diameter of the glands, or the spaces occupied by them, generally equals the thickness of the stroma separating the adjacent glands, but variations are very considerable in different sections of the intestine. The gland openings and the spaces occupied by the glands are regularly round, and only in the carnivora under a strong distension of the intestinal wall does their shape become angular. The picture of such a distended mucous membrane resembles a honeycomb.

The density of gland openings varies both individually and in the subdivisions of the intestine; the variation between the species appears less characteristic. In the strongly distended large intestine of the cat their number in 10 sq. mm. ranges from 500 to 1000, being greatest in the initial part and declining in the caudal direction. Also in the distended intestine of the dog in the aforesaid area their number ranges from about 450 to 750. In the undistended large intestine the density of the gland openings proves to be greatest in the sheep (500—1600), in the ox and pig their number amounts at most up to 1000, and in the horse their number fluctuates in the proximity of 1000, being in the sheep, pig and horse a little smaller in the caecum and the rectum than in the intermediate parts.

The total number of gland openings in the large intestine, a matter concerning which more detailed data have been presented elsewhere (TEHVER and REMMEL, 1939), averages 1,6—2,3 millions in the cat, 2,1—4,7 millions in the dog, 40—50 millions in the sheep, c. 90 millions in the pig, 107—154 millions in the ox and about 200 millions in the horse.

#### SUMMARY.

In the present paper the shape, approximate dimensions, relative, or total number, and the mutual connections or relations of the micro-relief elements of the gastro-intestinal tube of domestic mammals (horse, ox, sheep, pig, dog and cat), as revealed by surface examination, are described and demonstrated photographically.

In the stomach ribbons of the mucosa cut out along the great and small curvatures, extending from the cardia or plicated border to the pyloric orifice, were examined. In the small intestine short segments of the intestinal tube, originating from the initial part of the duodenum, from the ileum and from three intermediate parts, separated from one another by equal distances were subjected to investigation. In the large intestine the material for investigation came at least from every anatomical subdivision. Material from 5 to 10 animals of each species was used.

The micro-relief elements of the stomach proper, gastric foveolae, interfoveolar septa and gastric villi differ greatly in various species of domestic mammals. They are all represented simultaneously only in the pyloric part of the pig's and horse's stomach.

The gastric villi arising from the free edge of the interfoveolar septa are completely absent in the abomasum of the ruminants and may occur in domestic carnivora only exceptionally in form of functional structures, disappearing if the mucous membrane is distended.

The foveolae, mostly slit-like in a freely contracted stomach, are polyglandular in domestic carnivora, the horse and pig, but predominantly uniglandular in ruminants where they resemble the long tubular ducts of simple or occasionally branching gastric glands. The foveolar openings are partly concealed in the epithelium-covered mucosa of a freely contracted stomach by the protruding interfoveolar ridges, especially in the pyloric region. Only in the cardiac part of the pig's stomach do they seem to retain their regular shape, resembling the cells of the honeycomb. The depth and the diameter of the foveolae gradually increase towards the pyloric region, except in the pig, where they grow shallower in the intermediate part of the stomach. Their density, varying according to the distension of the mucous membrane, is greatest in the ruminants, where the number of the foveolae or gland openings averages in the undistended spiral fold of the sheep's abomasum c. 650 and in the ox from 145 to over 200. Generally their density decreases towards the pyloric orifice. The total number of gastric pits amounts in the ruminants to a little over 100 millions and in the dog to a little over 1 million. In the pig and horse their total number cannot be fixed with sufficient precision owing to their partially incomplete separation in the

intermediate part and owing to the closely placed gastric villi, concealing the foveolar openings in the pyloric part.

As regards the microscopic elevations in the inner surface of the small intestine, the domestic mammals are divisible into two groups, one of which, comprising the horse, dog and cat, has typical finger-shaped villi and the other, consisting of the ruminants and the pig, has a greatly varying relief picture, composed of reticularly arranged or separate folds, thin lamellae, or solitary villi of different shape.


The micro-relief picture peculiar to the adult ruminants and the pig differs in various subdivisions of the small intestine; generally such a change is brought about by the loosening of the network formed by the folds or lamellae and by the gradual fragmentation of the latter in the direction of the ileum. The mutual connections or anastomoses of the relief elements are accordingly most numerous and complicated in the initial part of the small intestine, and least developed at its end. Only in the initial part of the fourth quarter of the small intestine does one often see a reappearance of the network which was already loosened in the second and third quarters of the same animal. The transversal orientation of the folds or lamellae becomes more apparent in the middle or in the caudal parts of the small intestine. The conical or leaf-like projections arise in these animals generally from the free edge of the folds or lamellae, and only in the posterior parts of the intestine, where the fragmentation of the lamellar structures has turned them into tongue-shaped, leaf-like or conical villi, do they arise directly from the free surface of the propria. The gland openings are situated between the microscopical elevations and only in the pig can one find them exceptionally in the ridges of low folds.

In the species with cylindrical villi (horse and carnivora) the relief picture is quite uniform throughout the small intestine, except at its beginning where flattened villi occur in carnivora. The total number of villi in the small intestine of the horse is about 50 millions, in the dog from 1,3 to 1,7 millions and in the cat about 1 million. The total number of gland openings in the small intestine of the dog is over 6 millions. The increase in the number of relief elements (villi, gland openings) is not terminated at the time of birth.

The large intestine of all the domestic mammals presents

quite a uniform picture, being devoid of villi; the gland openings are dispersed evenly, without definite arrangement in adult animals. The density of the gland openings in the large intestine of the ruminants and the pig is greater than it is in the small intestine of the same species. Their total number has been estimated in all species of domestic mammals.

The differing relief picture found in the lymph follicles has not been dealt with in the present paper.



## REFERENCES.

1. Bujard, E. (1909): Etudes des types appendiciels de la muqueuse intestinale, en rapport avec les régimes alimentaires. Morphologie comparée. Sitiomorphoses naturelles et expérimentales. Intern. Monatschr. f. Anat. und Physiol., Bd. 26.
2. Ellenberger, W. (1911): Der Verdauungsapparat. In: Ellenberger, Handbuch der vergleichenden mikroskopischen Anatomie der Haustiere, Bd. 3. P. Parey, Berlin.
3. Forssell, G. (1928): Normale und pathologische Reliefbilder der Schleimhaut. Verh. Ges. Verdauungskrkh. Thieme, Leipzig.
4. Grettve, S. (1936): Morphologische und tierexperimentelle Studien über das Schleimhautrelief des Magen-Darmkanals. Acta Radiol., Suppl. 31.
5. Heidenhain, R. (1888): Beiträge zur Histologie und Physiologie der Dünndarmschleimhaut. Pflüger's Archiv, Bd. 43, Suppl.
6. Heiderich, F. (1911): Zur Histologie des Magens. I. Das Oberflächenepithel. Anat. Hefte, Bd. 43.
7. Hilton, W. A. (1902): The morphology and development of intestinal folds and villi in vertebrates. Amer. Jour. Anat., vol. 1, 4.
8. Jacobshagen, E. (1937): Grundzüge des Innenreliefs vom Rumpfdarm der Wirbeltiere. Anat. Anz., Bd. 83.
9. Jacobshagen, E. (1937): Mittel- und Enddarm (Rumpfdarm). In: Bolk, Göppert, Kallius und Lubosch, Handbuch der vergl. Anatomie der Wirbeltiere, Bd. 3.
10. Johnson, F. P. (1913): The effects of distension of the intestine upon the shape of villi and glands. Amer. Jour. Anat., vol. 14.
11. Kask, A. (1938): Das Relief der Magenschleimhaut einiger Haussäugetiere. Akad. Loomaarstit. Seltsi Aastaraamat II. Tartu.
12. Mall, J. P. (1888): Die Blut- und Lymphwege im Dünndarm des Hundes. Abh. math.-physik. Classe der Kgl. Sächs. Gesellsch. der Wissenschaften zu Leipzig, Bd. 14, 3.
13. Martin, F. P. (1906): Vergleichend-histologische Untersuchungen über den Bau der Darmwand der Haussäugetiere. I. Mitteilung: Über Gestalt, Lage und Länge der Darmeigendrüsen und der Zotten, sowie der Membrana propria. Arch. f. wiss. und prakt. Tierheilk., Bd. 32, 3.
14. Matthias, W. (1910): Vergleichende histologische Untersuchungen über den Bau der Darmzotten und Versuch einer Berechnung ihrer Oberfläche bei verschiedenen Haustieren. Diss. Bern.
15. Patzelt, V. (1936): Der Darm. In: Möllendorff, Handbuch der mikroskopischen Anatomie des Menschen, Bd. 5, 3.

16. Plenk, H. (1932): Der Magen. In: Möllendorff, Handbuch der mikroskopischen Anatomie des Menschen, Bd. 5, 2.

17. Rollet, A. (1871): Bemerkungen zur Kenntnis der Labdrüsen und der Magenschleimhaut. Untersuchungen aus dem Institut f. Physiologie und Histologie in Graz, Heft 2.

18. Sappey, C. (1894): Traité d'anatomie générale, p. II. Paris.

19. Schriever, O. (1899): Die Darmzotten der Haussäugetiere. Diss. Giessen.

20. Tehver, J. (1938): The micro-relief elements of the digestive tract in domestic mammals. Vet. Medicine, no. 4.

21. Tehver, J. and N. Remmel (1939): Über die Zahl der Dickdarmdrüsen bei den Haussäugetieren. Zeitschr. f. mikr.-anat. Forschung, Bd. 45.

22. Vau, E. (1932): Histoloogilisi uurimusi koduimetajate peensoole dimensioonasetest ja struktuursetest erinevustest. Manuscript. Estonian.



## EXPLANATION OF FIGURES IN TABLES I—VII.

All the illustrations appended to this work are unretouched micro-photos prepared by the author himself. The magnification rates used are 7,5 (scale A), 20 (scale B) and 80 (scale C). With the exception of figs. 5 & 6 in table IV and fig. 4 in table V all the others have been prepared with reflected light, the exceptions by transilluminating the preparations.

Tables I and II represent the micro-relief of the stomach from all domestic animals, tables III & IV — micro-relief pictures of the small intestine of the sheep, table V — those of the small intestine of the ox, table VI — those of the small intestine of the pig, and table VII represents besides the villi of the small intestine of the horse, dog and cat also the micro-relief of the large intestine in two photos.

TABLE I.

The relief elements of the stomach (and oesophagus): gastric foveolae, interfoveolar septa and gastric villi.

Fig. 1. Epithelium-covered surface of the mucous membrane of the oesophagus in the neighbourhood of the pharynx. Dog, male, 7—9 months old (German shepherd, mixed breed). Magnification 20 x.

The epithelium, even on its free surface, is pierced through by the irregularly placed openings of the gland ducts, which owing to their mucous content, stained electively by thionin solution, appear here as black rounded dots. The density of these openings increases toward the cardia. Their total number in the same dog amounted up to about 40 000. The unevennesses of the propria are disguised here by the surface epithelium, therefore their relief pictures are not derivable from one another, as happens in the glandular part of the stomach and intestine where the thickness of the epithelium is uniform.

Fig. 2. The micro-relief of the dog's stomach (large curvature c. 5 cm. away from the cardia). Gastric wall strongly distended. Mucous membrane epithelium-freed. Dog, male, 8 years old. Magnification 80 x.

The foveolae, resembling the foot-prints of a cat, are very low owing to a strong distension, and therefore their bottoms, mostly pierced through by 3—5 gland openings, are well visible. The interfoveolar septa have become thick and even on the free edge. The micro-relief of the distended mucous membrane from the corpus of the cat's stomach resembles this picture almost completely.

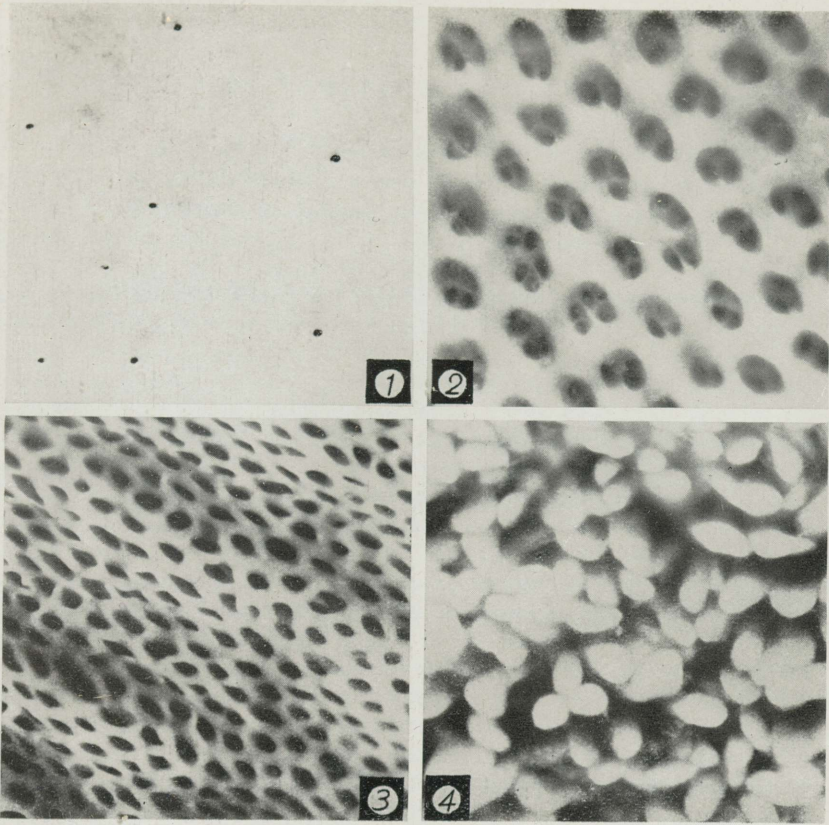
Fig. 3. Slightly distended epithelium-freed mucous membrane from the pyloric canal of the dog. Dachshund, male, 15 years old. Magnification 20 x.

Owing to the great depth of the foveolae, their bottoms are not visible here. Projections suggestive of gastric villi are lacking on the free edge of the interfoveolar septa.

Fig. 4. Epithelium-freed mucous membrane, covered with villi from the pyloric region of a freely contracted stomach. Pig, female, live-weight 230 kg. Magnification 80 x.


Villi, tongue-shaped or cylindrical at the tip, rising in a wide base from the interfoveolar septa completely conceal the foveolae and septa beneath them. It is only in the horse and the pig that such typical gastric villi occur in domestic mammals.

TABLE I.



SCALES

A 7,5 X



B 20 X



C 80 X

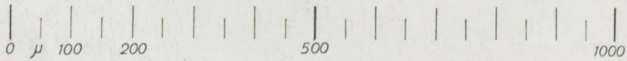




TABLE II.

The micro-relief of the stomach in domestic mammals. Twenty-fold magnification in all illustrations, except in fig. 5, magnified 80 times.

Fig. 1. Transition of epithelium-freed cutaneous mucous membrane into glandular in the stomach. Pig, female, live-weight 230 kg.

In the upper part of the illustration one can see the lined up papillae of the propria of the cutaneous mucous membrane and in the lower part of the figure gastric foveolae with septa between them.

Fig. 2. Epithelium-covered mucous membrane from the corpus of the dog's contracted stomach (large curvature, about 7 cm. away from the cardia). Boxer, male, 7—8 years old.

Slightly convoluted, interfoveolar septa occur here in the shape of folds between which slit-like solitary or confluent foveolae are seen.

Fig. 3. Epithelium-covered surface of the mucous membrane from the corpus of the grown-up cat's stomach. Gastric wall slightly distended.

The foveolae are slit-like here, and the free edge of the septa between them is more or less even. In a freely contracted stomach the free edge of the interfoveolar septa assumes the shape of a convoluted fold and thus the relief picture resembles fig. 2 in the same table.

Fig. 4. Epithelium-freed surface of the mucous membrane from the cardiac part of a spiral fold in the abomasum of a two-year-old sheep.

Predominantly uniglandular foveolae (dark dots) occur here as very slender and densely dispersed, long, tubular gland ducts. In the ox we find a similar picture, except that the diameter of the foveolae in the ox is nearly twice as great as in the sheep.

Fig. 5. Epithelium-freed surface of an undistended mucous membrane from the fundic region of the pig's stomach. Pig, castrated male, live-weight 80 kg.

The regular honeycomb-shaped foveolae of the cardiac part of the stomach have been replaced here by low depressions of irregular shape and size. Their separation from one another is often imperceptible. The picture resembles the relief of the sheep's duodenum (table III, fig. 2) in miniature. The number of the foveolae in the area in question can be fixed only approximately.

Fig. 6. Epithelium-covered surface of the mucous membrane from the pyloric canal of the strongly distended stomach of a grown-up cat.

The picture resembles the ordinary micro-relief of the mucous membrane in the cardiac part of the stomach. The villiform structures are completely lacking here.

Fig. 7. Epithelium-covered mucous membrane from the pyloric canal of the freely contracted stomach of a grown-up cat.

Such a granular appearance of the mucous membrane of the pyloric region which is not peculiar to all cats is only functional: the irregular

villiform structures we see here disappear in a distended mucous membrane or persist exceptionally as very low wavy elevations on the free edge of the interfoveolar septa. Here, as in the dog, we might, therefore, speak of pseudovilli and not of preformed and permanent villiform structures.

Fig. 8. Epithelium-covered surface of a freely contracted mucous membrane from the small curvature (5 cm. away from the plicated border) in the stomach of the horse. Thoroughbred English gelding, 2 years old.

The typical villi gastrici that can be seen here remain, as in the pig, even under a strong distension of the gastric wall. Foveolae and interfoveolar septa are completely concealed by them but are revealed in the distended mucous membrane.

Fig. 9. Epithelium-covered surface of a freely contracted mucous membrane from the neighbourhood of the pyloric orifice in the abomasum of a two-year-old sheep.

The diameter of the foveolae is here considerably greater than in the region of the spiral folds, and the septa between them protrude slightly in the shape of delicate ridges. Villiform structures are always, as in the ox, lacking.

Fig. 10. Epithelium-freed surface of the slightly distended mucous membrane from the vicinity of the pyloric orifice in the abomasum of the ox. Cow, calved 9 times.

By contrast with the sheep the free edge of the interfoveolar septa remains even here and the tubular foveolae look, therefore, like holes pricked into an inelastic substance. The interfoveolar ridges concealing the foveolae occur in the ox only exceptionally.

TABLE II.

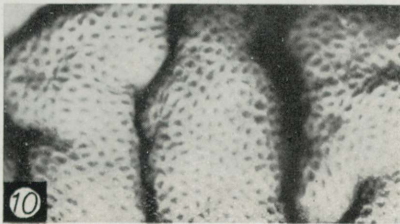
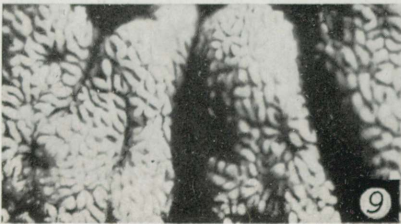
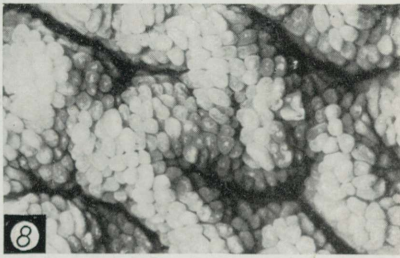
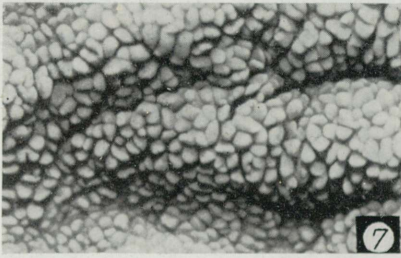
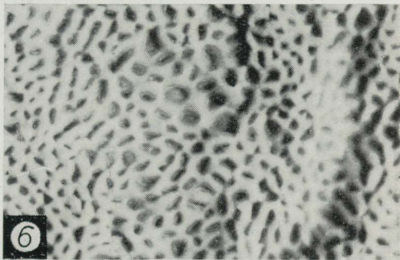
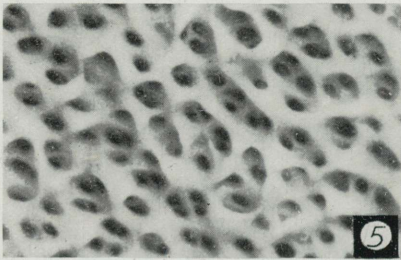
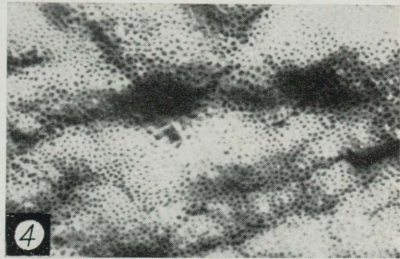
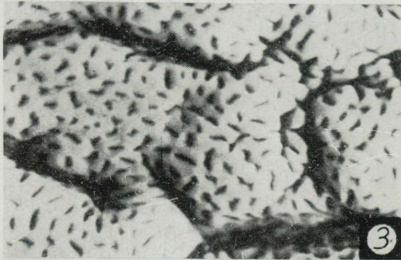
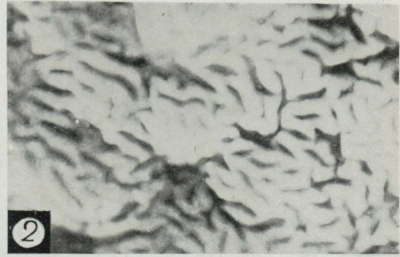
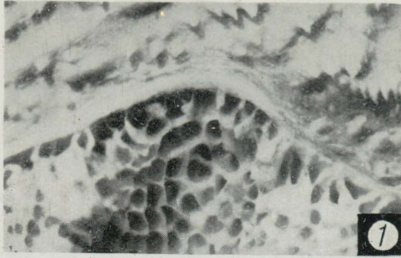
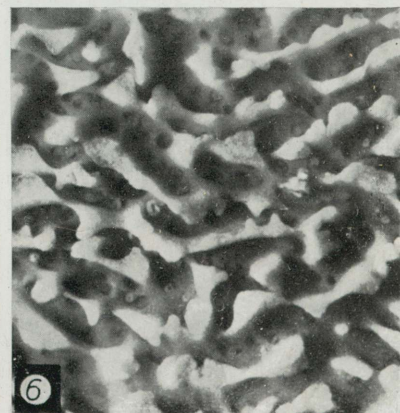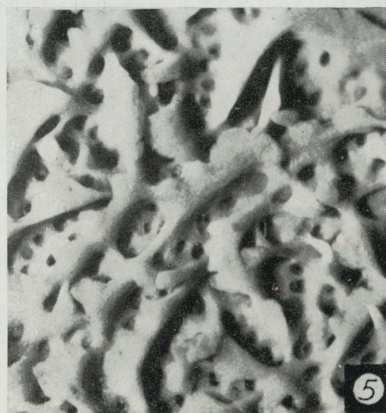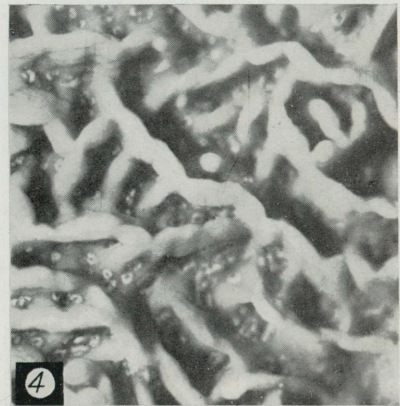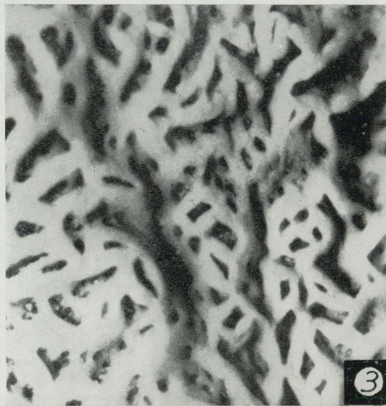
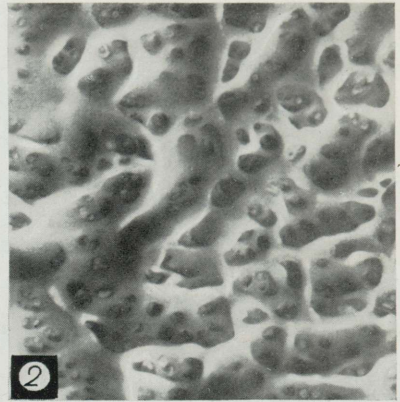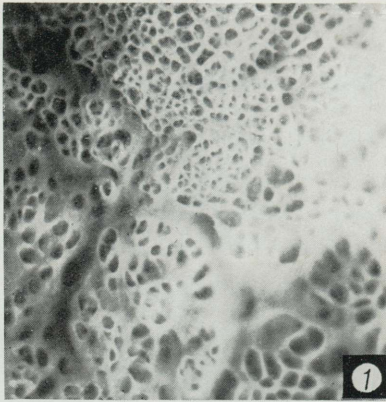


TABLE III.



## TABLE III.

The micro-relief of the epithelium-freed mucous membrane from the initial parts of the first and second quarters of the small intestine in the sheep. Twenty-fold magnification in all illustrations. The direction of the long axis of the intestine is here, as in tables IV, V & VI, from above downwards.

Fig. 1. The micro-relief of the duodenal mucosa at the level of the pyloric orifice. Sheep, female, 10 months old.

Fig. 2. Duodenal mucosa 5 cm. away from the pyloric orifice. Sheep, male, about 1 year old.

Fig. 3. Duodenal mucosa 5 cm. away from the pyloric orifice. Sheep, male, grown-up.

Fig. 4. Duodenal mucous membrane 10 cm. away from the pyloric orifice. Sheep, female, 15 months old.

With the exception of fig. 1, representing a picture peculiar only to the border between the stomach and intestine, the above figures exhibit the varying micro-relief of the intestine from one and the same level. As may be seen from the illustrations they all have in common an almost complete absence of villi. The elevations of the surface consist of irregularly anastomizing folds, with the intestinal glands opening into the meshes between them. The picture presented by fig. 4 also occurs exceptionally at the beginning of the second quarter of the intestine.

Fig. 5. The beginning of the second quarter of the small intestine. Sheep, female, 15 months old.

Fig. 6. The beginning of the second intestinal quarter. Sheep, female, 2 years old.

The folds in this part of the intestine have an irregularly dentated free edge. The course of the folds and the rate of their connections vary greatly.

## TABLE IV.

The micro-relief of the epithelium-freed mucous membrane from the beginning of the third and fourth quarters of the small intestine and the end of the ileum in the sheep. Twenty-fold magnification used in all illustrations.

Fig. 1. The middle of the small intestine. Sheep, female, 15 months old.

Fig. 2. The middle of the small intestine. Sheep, female, 2 years old.

Both these illustrations are peculiar to this part of the intestine. They show low, mostly transversally arranged folds from which high, broad-based villi take their origin.

Fig. 3. The beginning of the fourth quarter of the intestine. Sheep, male, 9—12 months old.

Fig. 4. The beginning of the fourth quarter of the small intestine. Sheep, female, 4 years old.

Of the highly varying micro-relief elements of this part of the intestine fig. 3 represents leaf-like villi arising in broad bases directly from the propria; between them one can easily see the tips of the slightly protruding upper parts of the intestinal glands. The relief represented in fig. 4 is formed by anastomizing low folds devoid of villi.

Fig. 5. The end of the ileum. Sheep, female, 3 years old. Trans-illuminated (elevations appear darker on the illustration).

Fig. 6. The end of the ileum. Sheep, female, 2,5 years old. Trans-illuminated.

In the first of these illustrations one can see conical solitary standing villi and short plates arising directly from the propria; the short folds or plates are arranged circularly round the lymphatic nodules. In the last illustration short, parallel, transversally placed folds with a wavy free edge are present.

TABLE IV.

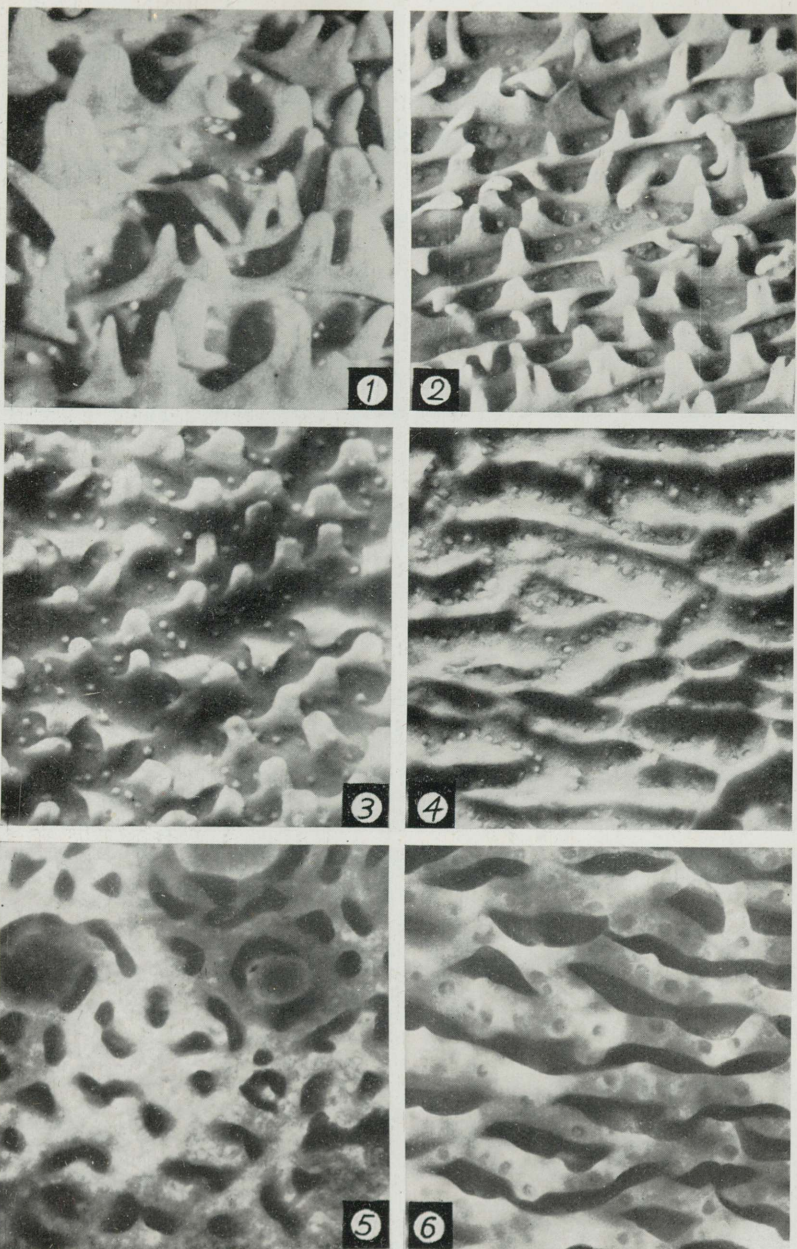


TABLE V.

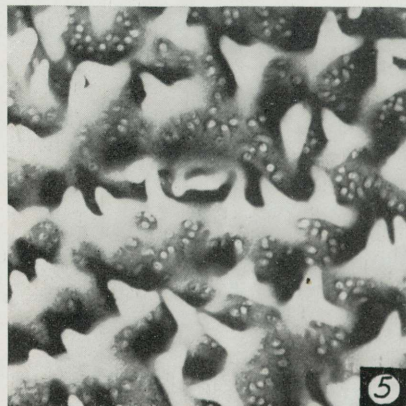
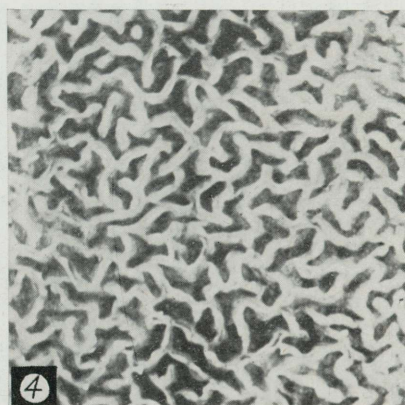
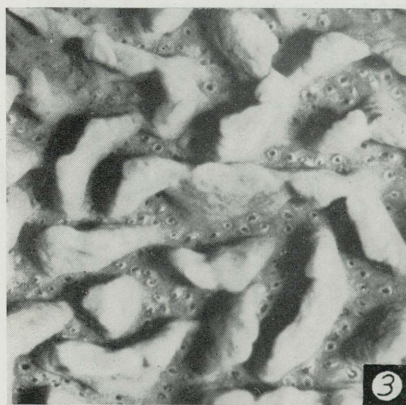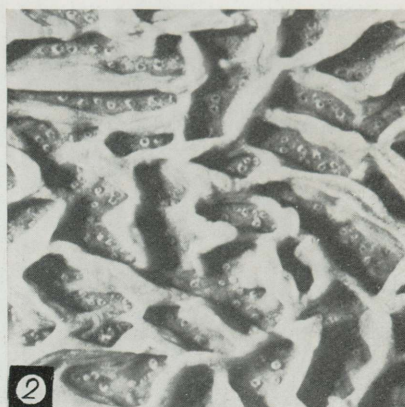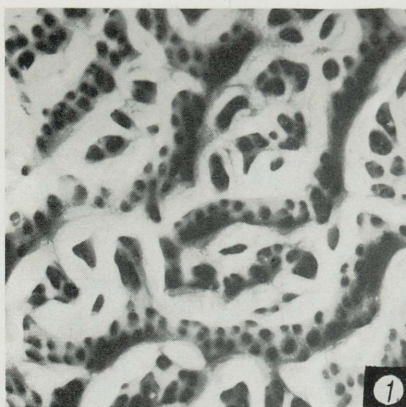


TABLE V.

The micro-relief of the epithelium-freed mucous membrane of the small intestine in the ox. With the exception of fig. 4, magnified 7,5 times, all the remaining illustrations have been prepared with a twenty-fold magnification.

Fig. 1. Initial part of the duodenum, c. 10 cm. from the pyloric orifice. Cow, calved 7 times.

The groups of intricately connected ridges are mostly separated from one another by comparatively broad flexuous streets. Such a picture occurs only in the very beginning of the small intestine.

Fig. 2. The beginning of the second quarter of the small intestine. Cow, calved 10 times.

Region of reticularly arranged folds. The villiform structures are replaced here only by the wavy free edges of the folds.

Fig. 3. The middle of the small intestine. Cow, calved 9 times.

The reticular arrangement of the folds has disappeared. The longer of the folds are situated transversally to the long axis of the intestine. The gland openings are arranged between the adjacent folds in a single row or irregularly.

Fig. 4. The beginning of the fourth quarter of the small intestine. Animal the same as in fig. 3.

Another region of the reticularly arranged folds in the small intestine. The separate folds are here, as in fig. 2, nearly wholly absent. Such an intricate connection of the folds is not characteristic of all the animals of the same species.

Fig. 5. Ileum of the adult cow.

Sharp conical villi are fused in their basal parts, thus forming mostly transversally placed folds. The arrangement of gland openings is irregular. This picture may be regarded as a transitional form between the folds and the wholly separated villi.

Fig. 6. Ileum. Cow, calved 10 times.

Another variety of the micro-relief in the ileum, consisting of transversally situated folds and of few conical villi. The gland openings here form a single row mostly. A still further variety of the ileum relief, not shown here, is represented by the surface covered with wholly separated conical or leaf-shaped villi.

## TABLE VI.

The micro-relief of the epithelium-freed mucous membrane of the small intestine in the pig. Twenty-fold magnification has been used in all illustrations.

Fig. 1. Initial part of the duodenum. Pig, female, live-weight 230 kg.

Two different networks of folds or lamellae are present here: that nearest to the mucosal surface consists of very delicate, low, intricately anastomizing ridges, and the other, nearest to the intestinal lumen with larger meshes consists only of basally anastomizing, low, triangular lamellae whose tips end in sharply conical prolongations. With the exception of the conical processes of the lamellae, not common to all animals, the picture presented here is typical in outline of the duodenum.

Fig. 2. The beginning of the second quarter of the small intestine. Pig, castrated male, live-weight 154 kg.

The picture, which may be found also in the third or fourth quarter of the small intestine of the pig, shows ramified and partly anastomizing folds, with very sharp blade-like edges, the course of which is straight, curved or convoluted. Between the folds one can find some tongue-like villi with conical tips. The delicate basal net-work is absent here.

Fig. 3. The beginning of the third quarter of the small intestine. Pig, castrated male, live-weight 85 kg.

The projecting relief-elements are represented here by ramifying lamellae, which may be regarded as parts of the net-work, the partial retrogression of which has taken place in the middle between the adjacent anastomizing points of the lamellae. Many of the branches do not reach up to the various edge of the lamellae and appear therefore as triangular supporting plates to the proper lamella.

Fig. 4. The beginning of the fourth quarter of the small intestine. Pig, castrated male, live-weight 79 kg.

A further example of the relief picture, which may be found in all three intermediate segments of the small intestine of the pig. The mostly triangular sharp-edged lamellar plates end in two or many sharp conical projections. The course of the lamellar folds becomes transversal.

Fig. 5. The end of the ileum. Pig, castrated male, live-weight 85 kg.

Transversally arranged leaf-like lamellae, some of which are fused in their basal parts.

Fig. 6. The end of the ileum. Pig, castrated male, live-weight 79 kg.

The relief represented here occurs in the ileum only in parts. It resembles the duodenal relief of the same animal and to a certain degree also the pyloric macro-relief of the pig. Its occurrence in the ileum is to be regarded as exceptional.

TABLE VI.

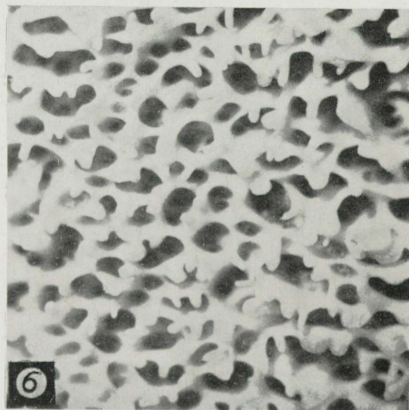

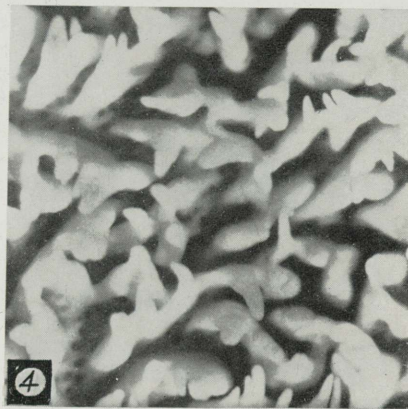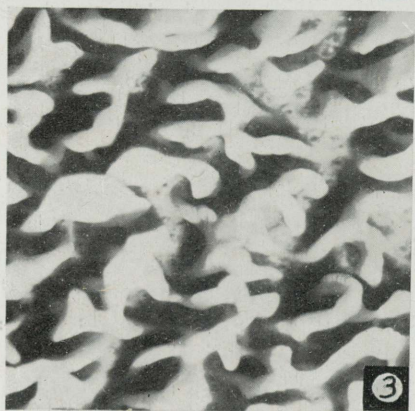
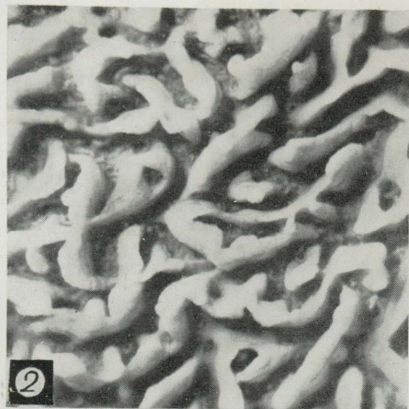
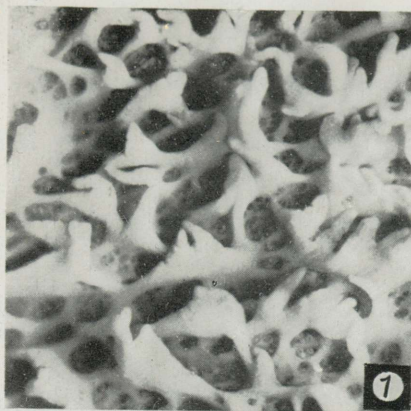
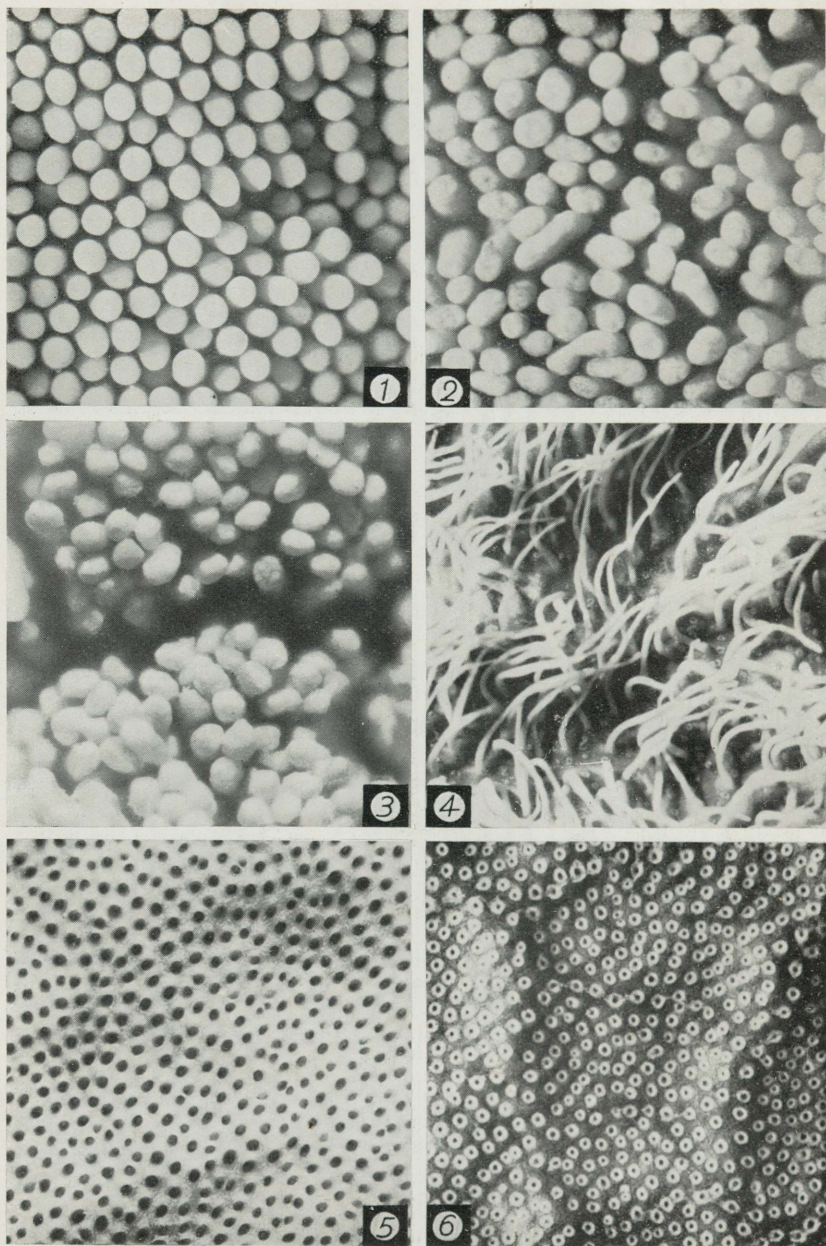


TABLE VII.



## TABLE VII.

Surface microphotographs from the small intestine of animals possessing cylindrical villi, and two illustrations from the large intestine. Except fig. 3, magnified 38 times, twenty-fold magnification has been used in all other illustrations.

Fig. 1. Duodenum of the adult female horse. Intestinal wall not distended.

The epithelium-covered villi have a more or less equal height, equal diameter, a cylindrical form and rounded tips.

Fig. 2. Moderately distended duodenum of the dog (male, 16 years old).

Between the typical finger-shaped villi (epithelium covered) one finds many flattened ones, the number of which is still greater in the very beginning of the duodenum, where they are situated transversally.

Fig. 3. The middle of the small intestine from the adult cat.

This photograph has been taken from the preparation made by SCHMELZER'S method which is accompanied with a considerable shrinkage of the villi; the actual diameter of the cylindrical villi does not greatly differ from those in the horse or dog.

Fig. 4. Epithelium-freed villi from the ileum of the adult cat.

The core or the stroma of the villi is represented here in the form of long (over 1 mm.) threads, which are inserted into the mucosal surface separately. Between their bases the gland openings are visible. In most preparations the epithelium-freed villi appear to be much thicker and lower than here, a fact which points to the great variability of their dimensions.

Fig. 5. Epithelium-freed surface of the large intestine of the male sheep (c. 1 year old).

Owing to the absence of the villi one sees here only the even cribriform surface which is quite similar in all domestic mammals. The dark round dots in the illustration do not correspond to the gland openings, but represent the cylindrical depressions in the stroma, which are evacuated of their contents, i. e., the glandular epithelium. Note the numerous bifurcating or isogenic lumina characteristic of young animals.

Fig. 6. Inner surface of the caecum of the pig (male, 8—10 months old).

Only the surface-epithelium has been desquamated here. The upper parts of the propria glands appear in the photograph as lighter circles, which surround the gland openings or glandular lumen. There is noticeable a certain linear arrangement of the glands.

ESTICA

A-7223