


pa.

Ex. A - 1617

Ты бока бама сими
проперсору модну мар-
минову Туцену - пер-
буи перамни ирпидеро
приснамет на ро урениа.

A. Miller

25/12-24. Tartu.



*From the Laboratory of the Clinic for Nervous Diseases, Tartu University.
Dir. Prof. L. Puusepp (L. Püssep).*

Sympathetic Ganglia Alterations Produced by Experimental Anemia. ¹⁾

By Alexander Schmalz.

I. Short Account of Sympathetic Ganglia Alterations in Various Pathological Cases.

Already Tanquerel de Planches (1839) and Brochmann (1851) described pathological anatomical alterations of the plexus solaris on the occasion of chronic lead intoxication. With increasing knowledge of the sympathetic nerves and their comprehension in the Autonomie System, their innervation of capillars, striated muscles, bowels and of some endocrine glands (Langley), the interest taken in sympathetic ganglia pathology has markedly increased, since the sympathetic ganglia represent so to say stations through which the impulses are going to the vegetative organs. In the end of the 19-th and in the beginning of the 20-th centuries there had been a great many of studies dealing with pathological sympathetic ganglia alterations in various pathological states of the organism.

Nevertheless in the literature accessible to me I could not find any dates relative to sympathetic ganglia alterations caused by local anemia; only Staemler, reviewing a case of pure anemia, noted atrophic cells in the ganglion cervicale superius and in the ganglia coeliaca. Abrikossoff in some cases of anemia gravis described hemosiderine, as a product of local blood decomposition, enclosed in the connective tissue of sympathetic ganglia. Staemler found sings of atrophy in nerve cells on the ground of arteriosclerosis. He described vacuolation of plasm, alterations of tigroid substance, tumefaction and shrinking of cells. Sympathetic ganglia alterations by anemia perniciosa had been reviewed by the before named authors and also by Spiegel and Adolf. Sings of cell atrophy there had been remarked in all cases.

The influence of combustion on sympathetic nerve cells had been investigated by Korolenko, Spiegel and Adolf, Staemler and Uskow. The results were concordant, therefore I will report only some experiments accomplished by Korolenko on rabbits. The rabbits were burnt by satigated steam of 1,5 atmosphere pression. A variably long time

¹⁾ Awarded with First prize by the Faculty of Medicine, Tartu University.

after the combustion the rabbits were killed. Their plexus coeliaci were dyed with Grenacher's alum carmin and complementary coloured with eosine (1% in water). The objects were digested in 90% alcohol. The author divided his results into two parts: to the I part belonged data relative to rabbits perished no longer than 5—30 minutes after the combustion (absolute lethal combustion). To the II part belonged animals which lived longer than 24 h. after the combustion.

In all cases acute affections of the sympathetic nerve tissue were indicated. In the first part the alterations were sharper than in the second. The plasm was turbid and clot together into little lumps of various shape and dyed intensively. By contraction of plasm were formed pericellular spaces. The nucleus sometimes kept its normal blisterlike frame. Then it was transparent and slightly reduced in size. Together with them there were noticed much more degenerated nuclei, very visibly reduced and uniformly dyed.

This stage of degeneration by Korolenko was called „Coagulation“.

It was observed mainly in those cases of combustion, which rapidly lead to death.

The second category showed the like symptoms of degeneration, but of a slighter degree: the plasm partly had shrunk and filled no more its capsules, it was of a fainter tint, clearer than that of the first category and enclosed a lot of grains. The cell capsules in parts were well outlined. The nuclei had a blisterlike shape and proved enlarged. This process the author named „Tumefaction“.

After „Coagulation“ regeneration is proceeding very slowly; after „Tumefaction“ the tissue regains its normal appearance in a comparatively short time. Thus the quoted author gives a clear picture of sympathetic cell affections in acute progredient cases. I obtained similar results by local anemia of short duration. Staemler observed the same phenomena.

Spiegel and Adolf in a case of death in consequence of combustion described sympathetic ganglia alterations as follows: decay of tigroid, intensively dyed homogeneous plasm.

The effect of starvation upon the sympathetic ganglia had been explored by Rosenbach, Issaieff, Uspensky, Zouboff, Statkewitch and others. An affection of nerve cells there had been noticed chiefly. Rosenbach in the cervical ganglion stated only a slight cloudy swelling of nerve cells.

Issaieff reported three experiments: 1) absolute starvation, 2) starvation with delivery of water and 3) reduced feeding.

In every experiment cloudy swelling of nerve cells, and vacuolation of their plasm had been stated. This author observed even a distinct perishing of some cells with karyolysis and plasm atrophy. Sympathetic ganglia from the intestines had been examined.

Uspensky (1896) and Zouboff (1903) reported in their dissertations data relative to sympathetic ganglia degeneration.

Uspensky found vacuolation of plasm to which succeeded shrinking of the nerve cells and their reduction to a homogeneously coloured bulk. The nucleus was reduced, sometimes it showed vacuolation; finally it decayed losing its shape and transforming itself into an intensively dyed body without observable structure.

Zouboff had made 20 experiments; he dyed his microscopic slides according to the Nissl method. Upon the whole, he stated the same alterations and found oblong spinous nuclei instead of the normal round ones.

Statkewitch by starvation obtained fatty degeneration of sympathetic ganglia.

Ignatofsky pointed out that the effusions of blood into the stomach coat in the cases of death from cold are dependent upon disturbances of the plexus solaris, which is the vasomotoric center for the digestion tract. By dying the microscopic slides according to Nissl, Ignatofsky made manifest nerve cells, a part of which were enlarged, by tumefaction,

another part having shrunk. The blood effusions were more or less expanded agreeing with the variably marked alterations of the sympathetic ganglia. The same author investigated the sympathetic ganglia of varnished animals and received tigroid decomposition, enlarged nuclei nearing to the cell lining. The plasm in its periphery parts exhibited a great many of vacuols; it was rarified and parts of it seemed unusually transparent.

Anfimoff demonstrated that varnishing of the skin produced an obvious injection on the ganglion cervicale superius; its capillars were overfilled with blood-globules, the parenchyma being tumefied and the nerve cells involving numerous vacuols.

The effect of some venena had been examined by several authors. The venena were given in small portions per os or injected under the skin. At different intervals the animals were killed and inspected.

By poisoning with opium, with the virus of dead bodies, with colchicine, with Berthollet's salt, phosphorus and with arsenic cloudy swelling fine granulation of plasm and vacuolation in the sympathetic nerve cells were perceived. (Ssemenoff and Petroff).

Spiegel and Adolf in a man of 21 years who died of salvarsan intoxication stated different kinds of tigrolysis, beginning dim pigmentation, homogeneous tumefaction of plasm, excentric position and unequal shape of the nuclei and round cell infiltration with neuronophagy.

Köster by intoxication with carbonic acid found similar alterations, he moreover described increased vacuolation of the plasm.

Mosse and Laignel Lavastine in lead intoxication obtained ring-shaped cells, and excentric position of chromatine in the nerve cells of plexus solaris. Kussmaul, Meier and Tranquel at the same kind of intoxication called attention upon the proliferation of parenchyma.

Abrikossoff in two cases of poisoning with sublimate and in a whole series of alcohol and denaturated spirit intoxication saw retrogressive alterations of sympathetic nerve cells: nucleus necrosis with pyknosis and karyorrhexis, disparition of tigroid and diffuse basophily of the plasm, and a modified shape of the nucleolus.

By infectious diseases all elements of the ganglia are altered.

Cases of typhoid fever and cholera have been investigated by Giuzetti, Iwanowsky, Kollanterians, Stomma, Petroff. These authors revealed analogical pictures: tumefaction of cells, atrophy, plasm vacuolation and appearing of round cells.

Shrivelling of the cells, loss of the nucleus and its transformation into a conglomerate of intensively dyed unequal granula in the third period of cholera had been reported by Iwanoffsky.

Issaieff in tuberculoosis met the same alterations; microbes in the sympathetic ganglia were not visible.

Brugia noticed constant chronic alterations dependent on pellagra: swollen parenchyma, sclerosis, enlarged lining of blood vessels. The nerve cells were reduced in number and size, and exhibited pigmentation.

Laignel Lavastine in 100 cases of infectious diseases found round cell infiltration in the parenchyma of sympathetic ganglia. Long lasting diseases caused sclerosis, marked increase of connective tissue, atrophy and pigmentation of nerve cells.

Staemler reviewed 150 cases of infectious diseases, from which 50 were pneumonia ending with death. He reported results as follow; loss of chromatine, marginal position of nucleus, pigmentation of plasm, shrunk cells, plasm vacuolation, increased parenchyma, overfilled blood-vessels in sympathetic ganglia. In one instance of death from pneumonia necrosis of cells has been described with empty cell capsules remaining after the disparition of cells, and structureless debris instead of nuclei.

Alterations of ganglia caused by constitutional syphilis had been observed by Satinsky, Petroff, Lanceraux, Leos Gross and others. In all instances similar sings of degeneration there were revealed: atrophy with pigmentation, colloid degeneration and interstitial tissue inflammation.

In cases of lunatics progressive paralysis hyperpigmentation, reduced number of nerve cells and increased connective tissue were noticed by Bonnet and Poincaré. Results of the same kind were obtained by Noera, Obersteiner, Hirschl, Laignel Lavastine, Caze-neuve and Marina. Noera described pigmentation, vacuolation and shrivelled nerve cells.

Spiegel and Adolf in cases of poliomyelitis saw chromatolysis both central and peripheral, diffuse infiltration with leucocytes and proliferation of blood-vessel endothel in the interstitium.

Alterations of sympathetic ganglia were stated in two cases of *ulcus rotundum ventriculi* by Spiegel and Adolf, they described pigmentation, widened nerve cell capsules and neuronophagy. Those alterations also might have been caused by the old age of the two individuals (71 and 67 years old) therefore the authors concluded that hitherto there had not yet been proved any dependency of the *ulcus rotundum* upon alterations of the sympathetic ganglia.

On the other hand Dalla Vedova by exstirpation of plexus solaris obtained symptoms of necrobiosis in the antrum pylori. Gundelfinger and Cobayaschi obtained conformable results; the first produced ulcera duodeni without failure of any experiment.

Lubimoff met nerve cell sclerosis, dimlutsre of plasm and complete disappearance of the nucleus produced by diabetes mellitus. Cavazzani at the same disease stated that it caused hyperemy, proliferation of connective tissue, partial atrophy of cells and pigmentation; the nuclei of some cells were unmistakably enlarged.

Diabetes insipidus caused fatty degeneration of nerve cells in the plexus solaris (Dickenson).

Addisson's disease caused proliferation of interstitial tissue in the plexus solaris, incrassated nerve sheath and fatty degeneration of cytoplasm (Wolff).

Bartsch in similar circumstances detected alterations of neuroglia and fatty degeneration of nerve cells. Further on pigment infiltration of cells (Andel) and colloid degeneration of cytoplasm (Fleiner) were described.

In 9 cases of Addisson's disease out of 54 sympathetic ganglia alterations were to be seen: pigmentation, cell atrophy, thickened cell capsules and infiltration (Kahlden). Brauer perceived tokens of degeneration in the interstitium, in the nerve cell and in the nerves. In 18 cases from 25 reviewed the ganglia appeared normal (Bittorf).

Spiegel and Adolf observed intensive pigmentation of all nerve cells; in some of them neuronophagy and a slight degree of round cell infiltration were to be met.

The majority of the authors assume that the above observed ganglia alterations seem to be merely secondary; they prove of no importance as to the etiology of Addisson's disease.

The ganglia might be affected by two means: 1) by intoxication which never fails to appear simultaneously with Addisson's disease; 2) by inflammation immediatly extending to the ganglion from the suprarenal glands.

The latter meaning is sustained by the fact that the plexus solaris is affected more frequently than the other more remote ganglia.

Basedow's disease exhibited proliferation of neuroglia and atrophy of nerve fibres (Virchow, Trousseau, Langeraux).

Spiegel and Adolf in two cases of Basedow's disease observed deepened pigmentation of nerve cells in the upper cervical ganglion; in some of the cells hyperemy and intensive round cell infiltration were visible.

Infiltration with a great many of round cells and increased neuronophagy can be apparent on cachectic states of the organism. Then enlarging of the nucleus in the interstitial tissue also becomes obvious; these symptoms prove the inflammatory character of the sympathetic ganglia alterations.

Kolien presumes that the main part of the alterations are secondary and of no importance to the proceeding of the disease.

By electric irritation of sympathetic ganglia baggy appearance and marginal position of the nucleus, enlarged size of nerve cells and augmentation of chromatine were obtained (Korbut-Dashkewitch, Vas, Ssadoifsky, Hodge).

Some authors discovered temporary changes in the sympathetic nerve cells depending on various physiological influences. Long lasting activity augmented the cytoplasm and its granula; in a state of fatigue the cells were reduced in number and in size (Lugaro, Eve). Schmaus by physiological irritation of ganglia received loss of Nissl substance.

Staemler perceived a certain relation between arteriosclerotic alterations in the body and affection of the sympathetic ganglia. In these cases arteriosclerosis was independent from age. In order to verify his induction, he injected to animals certain quantities of streptococcus albus cultures; after killing the animals there were found the same degenerations of sympathetic ganglia and sclerotic spots in the wall of the aorta and of other blood-vessels, conformable with the alterations observed on man in various cases of disease.

Another series dealt with intravenous injection of suprarenine. The results were the same. This outcome allowed the author to conclude, that there is a strict relation between the blood vessels and the sympathicus system. Moreover Staemler assumes that various toxic influences produce chronic indurative inflammation of the sympathetic ganglion, which leads to the destruction of nervous tissue.

According to the intensity of the nervous cell degeneration there will appear irritation or paralysis of the vasomotoric apparatus which produce functional disturbances, otherwise the sympathetic ganglia alterations cause degeneration of media and intima to which succeeds abnormally high blood pressure and thus the body becomes arteriosclerotic.

Analysing all reported facts one might presume that degeneration and sympathetic cell atrophy should be of the same kind in all diseases of the organism and they will be independent from the specificity of the injurious factor and will be caused barely by the intensity and the duration of the unphysiological irritation.

II. Methods of the Experiments.

The purpose of the experiments was to produce local anemia and to study the effect on the sympathetic ganglia. It was considered sufficient to compress the aorta abdominalis with a holdfast or simply with the finger. Thus the pelvis, the bowels, the abdominal sympathetic ganglia and the posterior extremities should become anemic. But soon it proved impossible to obtain constant results by this method and consequently a remaining ligature of the abdominal aorta was employed. This method procured constant results. The ligature was made extraperitoneal by using the advices given by Stannius (Pussep). An incision of 5—7 ctm. length was made on the back in the lumbal region on the left side and parallel to the vertebral column, 2—3 ctm. distant from it. The separated skin with the stratum subcutaneum and the fascia were retained on a hook by the assistant; then between the muscles sacrolumbalis and quadratus lumborum an incision was made precautiously without hurting the peritoneum. Next the finger was entered into the incision and between the named muscles and the peritoneum it was directed to the anterior side of the vertebral column, widening the wound. Before meeting the spine, the finger would touch

the musculus psoas major; it was taken on the hook and then the aorta was recognized by its pulsation; by widening the field of operation the aorta became visible. It was separated from the surrounding tissue without hurting the blood vessels, otherwise the picture would become unclear. The aorta was tied up on the height of the 4-th lumbal vertebra below the renal arteria, and above the arteria mesenterica inferior, near which the sympathetic ganglion mesentericum inferius is lying. After being tied up, the aorta becomes enlarged in its upper part, showing distinct pulsation, while the lower part appears collapsed and faint. The wound was washed with sublimate solution and then the muscle aponurosis and the skin were sewed. For the narcosis ether was used. Operated were cats and rabbits.

Some animals were killed a certain time after the operation, some were allowed to live until they died spontaneously. During the first 3—4 days, the animals were looked at every day, later on they were examined every second day. The feeling of smart, the tendon reflexes of the posterior extremities, the state of the muscles and the motoric functions were tested.

On each animal were drawn up detailed protocols; after their death dissections were made and the appearances of the organs were registered. To the microscopic examination ganglia solaria, ganglion stellatum, g. cervicale superius, g. dorsalia and ganglion mesentericum inferius were taken. They were fixed in 90% spirit, formol or Müller's fluid.

The second series were made for the purpose to examine the effect of acute anemia. Here the aorta was cut through on the level of the 2—3-th lumbal vertebra, below the arteria renalis. The upper part of the aorta was held with a pincette upon the test-tube, into which the blood was collected. At this moment the narcosis was interrupted. With each pulse the animal gradually was losing its blood and thus it perished. The moment of aorta discision and of death were put down in the records, also was the quantity of collected blood. The autopsy was made instantly after the death of the animal.

At the third series of experiments the animals repeatedly were deprived of a certain part of their blood in order to obtain chronic anemia. The blood quantity of the animal was found theoretically by using the ratio between the whole blood quantity of an animal and its weight. This ratio was found for rabbits and cats on the occasion of the II series experiments: by depriving the organism of blood until in the vessels and in the heart no blood was to be found, the whole blood quantity of the animal was stated and the ratio to its weight proved approximately constant. The blood was taken from the arteria femoralis. In both experiments the blood was let out two times. From the cat 45 cb. ctm. were taken; that is more than half of its blood. It was allowed to live 24 h. 68 cb. ctm. were taken on the whole from the rabbit and as it was its total blood quantity, the rabbit perished at the second operation.

I. Experiments on the compression of ligature of Aorta.

I Experiment. 1—VII—23. Grey and white male cat, weight 3800 gr. Operation according to Stannius. A remaining ligature was accomplished on the aorta. $\frac{1}{2}$ hour after the operation the cat is able to slight movements of the posterior extremities slowly flexing and deflexing them. Standing and walking proved impossible. The tendon reflexes and the feeling of smart are markedly reduced. The posterior extremities appear cool. The tail is rigid, half inclined and courbed on its proximal end. The anterior extremities have remained without disturbance. 1 hour after the operation the sensibility and the reflexes are reappearing. The cat stands already; when going it reels and drags the pelvis and the posterior extremities.

5.5 hours later, only a slight paresis of the posterior extremities is visible, they are dragging and prove a little spastic.

2—VIII. Cat has eaten nothing although it appears not ill, it drags quite unremarkably the posterior extremities, which are slightly spastic. Killed 24 hours later.

Dissection. Surroundings of wound are clean. Intestinal tract moderately filled with faeces, of normal appearance. Urinary bladder empty. Aorta is tied up tightly with a ligature near the 4—6 lumbal vertebrae. On the spot of the ligature a slight hyperemia is to be found, the upper part of the aorta being slightly enlarged. The lower part appears collapsed and faint, the blood being completely absent. The veins in the abdomen are enlarged and overfilled with blood. Liver, kidney, spleen, and stomach seem normal; the same are the heart and the lungs.

G. solare, g. stellatum, g. dorsale and g. mesentericum inferius were laid into 90% alcohol.

II Experiment. 2—VIII—23. Young female cat, white and grey, weight 1290 gr. Permanent ligature of the aorta on the height of the 4th lumbal vertebra. Symptoms similar to the former with automatic urinating and defaecation. They disappeared 2 h. after the operation, when only a slight paresis and spastic step were remarked. Killed 5 hours after the operation.

Dissection. Viscera without peculiarity. Blood vessel system like the former experiment. Fixed: g. stellatum, g. sol., g. mesentericum inferius, (90% alc.).

III Experiment. 15—VIII—23. Grey female cat. Stannius operation, 15 minutes later paralysis of posterior extremities. Is falling on the right side and lifting the hind feet. 25 minutes later, the cat can walk reeling and dragging the hind feet. Tendon reflexes are present. 40 minutes later the extremities are normal.

16—VIII. Cat appears healthy. Motoric and sensible functions, and the urinary bladder are normal. Slight rigidity of posterior extremities.

17—VIII. Same state. Killed 48 hours later. Sympathetic ganglia were conserved in 90% alcohol.

IV Experiment. 16—VIII—23. Well fed female cat, weight 2810 gr. Stannius operation. 10—15 minutes after the operation the motility was normal. Later it is dragging the pelvis and the posterior extremities. Simultaneously with the act of walking the spine is curving, which indicates, that in this act the spinal muscles now also are participating. Tendon reflexes and sensibility are markedly diminished 20 minutes after the operation.

35 minutes after that, strength and sensibility are reappearing fast and an hour later the cat walks yet dragging its hind feet.

17—VIII. Cat seems apathetic. Walks reeling and falls back on its hind feet. Increased muscle tonus in the posterior extremities and spastic symptoms, quick tendon reflexes are prominent.

18—VIII. Same state.

20—VIII. Cat has grown visibly thinner, ill conditioned. Tonus of posterior extremities has increased. Bladder without disturbances. Spastic step. Beginning atrophy of posterior extremities. Weight 2270 gr.

23—VIII. Same state. Atrophy has increased.

25—VIII. Sharp increase of atrophy. Faltering step, hesitating. Tendon reflexes diminished. Automatic defecation and incontinentia urinae.

27—VIII. Atrophy is proceeding; the muscles resemble thin cords. Cat moves with great difficulty and proves apathetic. Tendon reflexes have vanished.

28—VIII. Same state.

29—VIII. Cat perished in the night. Weight of the body 1875 gr. Before dying the cat has gnawed its left leg.

Dissection. Intestins filled with faeces. Stomach dilated. Urinary bladder empty. The kidneys appear normal. The liver is of a dim red tint and swollen. Thoracal organs without alterations. Venous system overfilled with dark blood. Sympathetic ganglia were fixed in Müller's fluid.

V Experiment. 18—VIII—23. Male cat, white and grey. Weight 1685 gr. Same operation. Tendon reflexes disappear. Pricking with a pin produces no reaction on the hind legs. Rigidity of tail. It remains lifted up during a longer time than in the previous experiments. One succeeds to incline it only by a certain effort and it instantly returns to its former position.

2,5 hours later the mobility and the sensibility are restored to a certain stage, also the tendon reflexes.

20—VIII. Cat is apathetic, moves feebly and tries to hide itself. Spastic step, moves vacillating. Tendon reflexes slightly increased, rigidity of the muscles.

22—VIII. Slight atrophy of the crural muscles, they seem thinner and meeker.

24—VIII. Same state, cat feels better.

27—VIII. Increasing atrophy of the posterior extremities.

29—VIII. Markedly worse state. Moves with great difficulty. Tendon reflexes weakened. Pricking with a pin causes reaction after 20 seconds. Urinary bladder without disturbance.

31—VIII. Worse state. Increasing atrophy. Muscles are changed into thin lamellas.

1—IX. Cat is very excited, tries to exit from the cage. Refuses food and drinking.

2—IX. Same state. 3—IX. Cat perished.

Dissection. Heart, lungs and liver are hyperemic. Urinary bladder proves diminished, shrivelled, with abnormally thickened walls. It contains a small quantity of turbid urine of a purulent aspect; the mucous membrane is found atrophic. The kidneys are darker than in the normal state. Venous system overfilled with blood. Field of operation normal. Fixed: g. stellatum, g. solare, g. mesentericum inferius.

VI Experiment. 19—VIII—23. Well fed female cat, pregnant. Stannius operation. Complete paralysis of the posterior extremities. Sensibility and tendon reflexes are defeating. Legs passively hang down, tail is lifted up and curved. Half an hour after the operation, the cat is beginning to walk, dragging the pelvis and the posterior extremities. 3 hours later same state.

21—VIII. The paralysis of the legs is remaining, tendon reflexes are missing, sensibility also. Refuses food and drinking, is excited.

22—VIII. In the morning abortus. Same state, refuses to eat and drink.

23—VIII. Cat perished.

Dissection. Digestion tract empty. The kidneys have a normal aspect. Urinary bladder is empty. Aorta and arterial vessels below the ligature are empty. On the spot of the ligature a thrombus of dark colour is found. Superior and inferior vena cava overfilled with blood, likewise the blood

vessels of the uterus. In the wall of the uterus blood effusions are to be seen. Liver looks dark. The lungs are normal. Heart bloodless. Conserved the former ganglia.

VII Experiment. 29—VIII—23. White female cat. Weight 1685 gr. Two ligatures on the aorta were made. Results like the former (vide exp. no. 6); 3 and $\frac{3}{4}$ hours later the paralysis is still persistent. 24 h. later flaccid paralysis of hind legs, and missing of tendon reflexes is noticed.

31—IX. Same state. Incontinence of faeces and urine. Refuses eating and drinking.

1—IX. Perished in the night.

Dissection. Swelling and enlarged size of the mucous membranes of the whole urinary bladder. U. bladder is widened, the walls are thin and contain thrombs. The membranes contain thrombs. On the spot of the ligature a thrombus is found. Fixed the same ganglia. The urine contains traces of blood.

VIII Experiment. 31—VIII—23. Young male cat. Weight 1850 gr. Operation. Results like experiment no. 4.

1—IX until 6—IX the cat feels well, eats and drinks.

7—IX. Same state. Is a little apathetic.

8—IX. Perished.

Dissection. Alterations of the urinary bladder, which is of reduced size. Atrophy of the bladder wall with a little necrotic spot of dark red colour. Blood effusions in the blood vessel wall. The inner layer of the urinary bladder wall is atrophic and shows dilated blood vessels. The bladder contains a small quantity of urine with traces of pus. Kidney dark brown. Alterations of the vessels like in the former experiments. Symp. gg. fixed in formol.

IX Experiment. 7—IX—23. White reddish female cat. Weight 2300 gr. Same operation. The effect vanishes 35 minutes after the operation. The cat then is able to walk yet a little vacillating. Tendon reflexes and sensibility are present.

8—IX. Cat goes lame on the right hind leg because it treads on the whole sole and the tibia. Incipient muscle rigidity on the posterior extremities. Tendon reflexes weakened.

10—IX. Muscle atrophy has increased. Weight 2200 gr.

11—IX. Increased atrophy, rigidity of the muscles is more pronounced on the affected side. Tendon reflexes scarcely perceivable. Walks like the day before. Killed.

Dissection. Normal organs except urinary bladder reduced in volume and urinary ways with beginning obliteration of the mucous membranes.

X Experiment. Young female cat. Weight 1625 gr. Stannius operation. At 1 h. 25 m. 2 ligatures were made on the aorta. 5 minutes later the cat moves in a mere springing way flinging itself forward with the whole body.

1 h. 35 min. Tendon reflexes absent on the left leg, where the operation was made. Rigidity of the left leg. Right without rigidity, tendon reflexes diminished. Sensibility is missing.

1 h. 45 min. Cat walks dragging the posterior extremities. Curved back. 1 h. 55 min. Tendon reflexes restored on the knee. Rigidity is decreasing. 2 h. 5 min. Walks a little vacillating flexing the soles of the posterior extremities. Feeble rigidity of both legs. Tendon reflexes are still restoring on the left leg, likewise does the sensibility. 2 h. 15 min. paralysis has become paresis. Cat is killed minutes after the operation.

Dissection. All organs offer a normal aspect. On the spot the ligature a slight blood effusion is visible in the surrounding tissue. Sympathetic gg. were fixed.

XI Experiment. 11—IX—23. Well fed female cat. Weight 2150 gr. Dark reddish colour. Stannius operation. Results like the for-

mer. Complete loss of tendon reflexes and sensibility. Excited state. 1 hour after the operation the mobility is quite restored.

12—IX. Cat appears healthy, eats and drinks. Only an insignificant rigidity of the posterior extremities is noticeable. Weak tendon reflexes.

13—IX. A beginning atrophy is perceivable on both legs. Tendon reflexes have disappeared. No filling of the urinary bladder is observable.

15—IX. Cat markedly has lost flesh. Atrophy and rigidity have augmented. Cat is apathetic but eats.

17—IX. Same symptoms. Alterations have increased.

18—IX. Cat is apathetic, walks with a limp like in experiment IX.

19—IX. Cat perished in the night.

Dissection. Hyperemy of lungs, heart, liver. Veneous system overfilled with blood. Sympathetic ganglia conserved like in the former experiments.

XII Experiment. 11—IX—23. Young grey female cat. Weight 1827 gr. Operation like the previous. $\frac{1}{2}$ hour after the operation the mobility is quite restored already. Tendon reflexes first were reduced, then restored quickly. Marked rigidity on both posterior extremities. Weakened sensibility.

12—IX. Cat feels well and moves sufficiently. On the posterior extremities nothing but a slight rigidity is perceivable.

15—IX. Same state.

16—IX. A trifling atrophy on the posterior extremities is appearing.

19—IX. Atrophy has increased, for the rest same state.

23—IX. Cat is in very good health, eats with appetite. Atrophy is not proceeding further.

26—IX. Same state.

28—IX. Except an inconsiderable rigidity, the cat appears normal.

30—IX. During the last days the atrophy has increased, the tendon reflexes and the sensibility have become scarcely noticeable.

2—X. Excited state, preceding muscle atrophy.

3—X. Apathetic behaviour. Cat has grown very lean in spite of good feeding with flesh. Weight 1335 gr. Thin and meek muscles. The tendon reflexes are noticeable. Slow reaction of sensibility. Incontinence of faeces and urine. Killed.

Dissection. Viscera without alterations. The arterious vessels, the arteria cruralis and the aorta abdominalis contain small quantities of blood. The former experiments. The field of operation is in good state. Fixed: g. dorsale, g. stellatum, g. mesentericum (superius) inferius.

Thus the above mentioned 12 experiments revealed concordant symptoms appearing in strict order of succession.

Instantly after the operation the posterior extremities appeared cooler, than in the normal state, their activity became limited. The knee and Achilles tendon reflexes were lowered, sometimes they even were missing. Pricking with a pin caused lazy reaction, at times the sensibility had vanished completely as in no. V, VI, II. The motoric functions of the posterior extremities were fully paralysed immediately after the operation. The animals then were walking exclusively by the aid of the anterior extremities and were dragging the posterior ones. The anterior extremities in all experiments remained entirely intact. The spine at the act of walking also was used. It was curved by spinal muscles and thus the posterior extremities were neared to the anterior ones. Rigidity of the tail was noticed in all experiments. It appeared instantly after the operation. Some animals suffered from incontinence of faeces and urine like in experiment no. II. It appeared within a short time after the operation.

The described period after the operation may be called „period of relaxed paralysis“. A variably long time later begins the restoration of the disturbed functions. In 9 cases the animals began to walk 30—60 minutes after the operation. In one case the mobility returned within 2 and $\frac{1}{2}$ hours and in experiment no. VI and VII the mobility was almost totally disturbed during the whole time the animals were living.

In the experiments on rabbits it was sufficient to compress the aorta completely during 15 minutes in order to obtain persistent paralysis of the posterior extremities without reintegration of their function. The restoration more easily appearing in the experiments on cats probably depends on their more developed collateral system. The failure of the restoration in experiment no. VII can be explained by the last period of pregnancy the animal was in. The operation with the narcosis and then the abortus of five dead embryos had weakened the organism of the cat so that it was not able to restoration. In experiment no. VII the persistency of paralysis cannot be explained sufficiently.

Next to the period of paralysis comes the period of restoration. The animals are walking but precautiously and vacillating. The posterior extremities are stretched and rigid. These are symptoms of a spastic state, which also is proved by the raised tendon reflexes. The sensibility returns to its normal state and thus after the period of restoration the animals might be considered as normal if the mobility was not slightly disturbed. The animals eat and drink and behave like normal.

The state of relative health with the majority of the cats lasted for 2—3 days; then succeeded a period of atrophy. The tendon reflexes were decreased; in experiment no. XII and IV they disappeared completely. The atrophy of the posterior extremities, once appeared, was proceeding every day; the muscles within 6—7 days changed into thin lamellas. The mobility of the posterior extremities decreased in spite of good feeding. During the last days of their life the animals became apathetic and ceased to eat. The day before their death many of the cats became excited. The cats which outlived a longer time exhibited incontinence of faeces and urine, which indicated a sphincter paralysis of the anus and the urinary bladder. Almost in all cases the autopsy showed alterations of the urinary bladder and of the urinary ways, which allow to assume that death was caused by alterations of the excretion organs. One might suppose, that the two cats perished from uremia caused by an ascendent pyelitis. The pus found in the urine rends it at least possible. Then the excitation and the convulsions can be considered as symptoms of uremia.

The rabbits showed retention of urine since the third day after the operation and, if not catheterized, perished from uttered uremia, with clonic and tonic convulsions and fibrillar oscillation. On the other hand the cats did not show dilatation of the urinary bladder like the rabbits, so that the urine was not retained in the bladder which often even seemed diminished, but was likely to depend upon affec-

tion of the ureter or of the pelvis renalis or of the kidney itself. Infection might have entered through the bladder. The cats lived after the operation from 55 minutes to 22 days. Well fed and young animals supported the operation better and lived longer than the others. Their weight decreased only during the last days before death, which was a distinct token of its approaching. In the last experiment the cat lived 22 days and was killed when it was refusing food and exceedingly lost flesh. It had lost 500 gr. of its weight.

II. Experiments on Acute and Chronic Anemia.

XIII Experiment. 7—VII—23. Young female cat. Weight 1025 gr. Operation: the cavum abdominis was opened and the aorta abdominalis was cut through. The blood was collected into a graduated test tube in the quantity of 49 cb. ctm. = 40 gr. The cat perished 4 minutes after the dissection of the aorta; first ceased breathing and a minute later the heart stood still. In the beginning the breathing quickened, deepened; finally it became approximately of the Sheyne-Stooke type, deep and slow with interruptions lasting 10—20 seconds and longer. While the blood was let out, the cat exhibited automatic releasing of urine. Dissection half an hour later.

All organs are anemic. Heart and arterious system are bloodless. Ganglia fixed.

XIV Experiment. 9—VII—23. Young dark rabbit. Aorta was cut near the second lumbal vertebre. All blood was let out. Lived 7 minutes after the operation. Symptoms like those of the former experiments. The blood remained unmeasured. During the operation in the aorta thrombs appeared two times, requiring a second dissection of the aorta.

Dissection. Complete anemia of all organs. Taken: g. solare, g. dorsale, g. cervicale superius.

XV Experiment. 9—X—23. Well fed reddish female cat. Weight 2395 gr. 28 cb. ctm. of blood were let out from the left arteria cruralis. The cat for some time becomes apathetic. Walks vacillating, but in a short time the walking becomes normal.

10—X. Apathetic, bad appetite, slight comatous state.

11—X. Same state, is not able to spring onto a low bench.

12—X. Second operation. From the right arteria cruralis 17 cb. ctm. of blood were taken. After the operation great weakness. Lies on the floor crying and does not move. Lazy rection of sensibility. The posterior extremities are to be felt unusually cold. Half an hour later the cat appears normal, is walking and sitting without disturbance.

The cat lost on the whole 45 cb. ctm. of blood — according to the above mentioned calculation, the total blood quantity of the cat must have been about 69 cb. ctm.

13—X. Cat is very apathetic, comatous. Pricking causes lazy reaction, it is impossible to make the cat cry by pricking it. Has grown markedly thinner. Weight 2005 gr. Within 4 days it lost 345 gr. of its weight. (390 gr. — the weight of the blood which was let out - 45 gr. makes 345 gr.) Tendon reflexes are normal. The cat is killed. Symp. gg. were fixed in alc.

XVI Experiment. 9—X—23. Reddish rabbit. Weight 2135 gr. 35 cb. ctm. of blood were taken from the arteria cruralis; that makes more than half of its total quantity, considering the weight of the rabbit. Apathetic state after the operation.

10—X. Good appetite. Feels well. Mobility still a little weak. Has grown thinner.

11—X. Same state.

12—X. About 30 cb. ctm. are let out from the arteria carotis communis. The rabbit showed utter weakness and was killed by taking the rest of its blood, which proved only 5 cb. ctm. The first portion poured out within two minutes, then the arteria was compressed and later on the rest was taken. On the whole the rabbit lost 65 cb. ctm., that makes the total blood quantity, which also agrees with the number found by calculation.

Weight of the body 1905 gr. Within 3 days the rabbit lost 230 gr. The collected blood had a weight of 68 gr., thus the (clean) net deficit of weight was 162 gr. Dissection: all organs bloodless, heart collapsed and empty, g. fixed in alcohol.

Description of Histological Pictures.

X-th Exp. 50 minutes after the aorta ligature, the histological picture inconsiderably differed from the normal one. In some cells the tigroid substance stained more densely and the tigroid granula appeared smaller. The nuclei of those cells appeared enlarged and were lined distinctly. Some cells exhibited a marginal position of the nucleus and of the nucleolus. The whole slide showed 2—3 cells remote from their capsule wall on one side and thus forming pericellular spaces. (Preparation of ganglion mesentericum.)

II-th Exp. 5 hours after the operation the sympathetic ganglia display sharper alterations. The majority of the cells are enlarged, the lining of them are not clear, the tigroid stains darker; in the shape of small granula it is equally spread all over the cell. The nuclei are enlarged, their contours are not sharp. The majority of the nuclei are situated near the periphery of the cells. The nucleoli are well visible. A few cells of diminished size (dependent on shrinkage) and even decaying cells are remarked. One of them is decomposed partially and has lost its nucleus which had fallen out from the surrounding plasm. Then there are visible cell debris, which stain intensively and involve granula of not yet decayed tigroid. Nucleus and nucleolus have vanished. Some neuronophages are to be found in the interstitial tissue. The carmine slide shows accumulation of chromatine round the nucleolus, while in the normal cells the chromatine is spread all over the nucleus, in the shape of fine granula. Some cells exhibit a yellow brown pigmentation, which rarely is to be seen in normal cells also, but then it is of a lower degree. In single nerve cells the nerve fibres are visible. They are of a faint tint, while the cell is coloured intensively.

I-st Exp. 24 hours after the operation a sharp alteration of the ganglion tissue is perceivable. A great many of cells are shrunken and appear oblong or ellipsoid. These cells stain more intensively, than the cells, which were affected less and preserved homogeneous nuclei and plasm. Some cells are decaying; their tigroid has melted and only near the cell limit a small portion of it still is remaining. A few cells offer a view of plasm dilapidation. Neuronophages appear in the connective tissue, aggregating round the decaying cells.

III-th Exp. 48 hours after the ligature the cells show greater alterations. They are of the same kind as in experiment no. II, but

the alterations are sharper and the number of affected cells is greater. Most of them are considerably enlarged and tumefied with vague contours. The plasm is of a darker tint, the chromatophile substance diffusely penetrates the plasm (tigrolysis). The nuclei have grown bigger and mostly are situated near the periphery. The nucleus is also frequently to be found near the nucleus margin. Other cells in limited quantities appear sporadically in the slide; they are shrivelled and their plasm has regressed from the cell capsule forming pericellular spaces. Single cells are less shrunken, others are filling only half of their capsules. Atrophic cells are to be met in a considerably greater number, than in no. II. In several cells the chromatophile substance is decaying and has lost its granular appearance, covering the cell like a subtile powder. In other cells the protoplasma begins to faint near the periphery. In some of them only mince bits have remained from the chromatophiles and are spread all over the cell body in disorder. In still other cells the plasm is completely colourless with exception of a small remainder of tigroid. The cell linings are not perceivable. The nucleus lies uncovered in the surrounding glia. Finally a dilapidated nucleusless mass is noticeable instead of the cell. The process of cell decay always is accompanied by the appearing of round cells resembling to leucocyts, the neuronophagues. Their task seems to be the eating up of ruined cells. One can see how the neuronophagues enter the cell from the periphery. Cells which preserved their shape and their body, but without nucleus, nor nucleolus, also are to be met. Their plasm stains intensively near its limit: marginal position of tigroid. Various cells contain a yellow brown pigment; in one of them it occupies half of the cell. These affected cells display vacuolation. The small round vacuols chiefly are near the cell margin. The nucleus and the nucleolus of the decaying cells are enlarged, the latter often is situated at the periphery. Sometimes the chromatine like a network surrounds the nucleolus and sends long slender processes to the margin of the nucleus. The Van Gieson staining betokes an augmentation of connective tissue.

VI-th and VII-th Exp. 3 days after the ligation of the aorta, most of the cells exhibit various shrunken shapes. Their plasm with thionine stains a more intensive blue than normally; single cells are so intensively dyed that the nucleus becomes invisible as it is staining the same tint. Other cells have spots of stained protoplasma. The intensively coloured cells appear homogeneous, because their structure is hidden by the dense colour. The lighter staining cells are filled with little granula or are wholly penetrated by a fine network of tigroid. Marginal position of tigroid also has been noticed. The nuclei of these stain just the same tint with thionine and are to be found only by the darker coloured nucleolus. The nuclei are well distinguishable in the lighter staining cells; in some places they prove to be enlarged. Among the others, cells with typical tigrolysis are to be seen.

Like in the former experiments, here various kinds of cell decaying also are observable, but here the perishing cells are considerable.

rably reduced in volume while in the preceeding experiments they were tumefied. The range of cell decomposition is like that in experiment no. III. First a minute part of the plasm begins to fade, then by and by the whole cell may become faint. The chromatophile substance in the beginning grows slender; afterwards it changes into small granula, which lie disconnected from each other near the cell border. In the centre the tigroid, has disappeared and the nucleus distinctly differs from the surrounding faded plasm. Neuronophages appear around the decaying cells or within them. Last perishes the nucleus after which a formless detritus remains from the cell, with neuronophages enclosed in it. Many cells involve small round vacuols principally near the cell lining.

IX-th Exp. 5 days after the operation the cells and their nuclei are enlarged, the cell membrane is thin like a cobweb and on its inner side it shows bits of chromatine while the middle of the cell contains no more of it. The nucleolus is enlarged; in some cells one can see how chromatine droplets are confluing with the nucleolus. Thus its bigness may become explained. The cell plasm exhibits granulation. In some cells remainders of tigroid are to be found. In their decaying parts neuronophages are visible. The cells are atrophic.

VIII-th Exp. 8 days after the aorta ligation all cells in the range of vision are diminished and altered in shape: there are round, oval, oblong, angular and other frames; somewhere the plasm is denticulated and excavated. The nuclei of many cells stain blue, the nucleolus is distinguishable in the structureless nucleus as a darker point (chromatolysis of the nucleus). The shapes of the nuclei also are very different; mostly oblong or ellipsoid nuclei with tapering ends are to be met; they are to be found near the periphery and prove considerably diminished in size. The immersion objective allows to perceive the nucleolus in the oblong, fusiform, homogeneous nuclei; in one of them the nucleolus is occupying the whole length of the nucleus being enormously enlarged relative to the latter. Several nuclei besides the nucleolus exhibit 2—3 drops of aggregated chromatine not differing in staining from the nucleolus. In others perinuclear spaces are to be noticed around the nuclei, like a shining border. The nuclei of less affected cells are bigger and rounder; their contours are not sharp. In a few cells no nucleus is perceivable. The plasm of the more normal cells stains densely and has the tigoide substance spread all over the cell body. In more affected cells with chromatolysis of the nucleus, the chromatophile substance occupies a denselier staining layer near the periphery, while the centre stains feebly (marginal position of tigroid). The plasm mostly shows vacuolation. Single cells involve small vacuols in the periphery and bigger ones near the nucleus. These cells are shrunken also. Instead of nucleus a large excavation is observable occupying half of the cell and containing grey structureless debris remaining from the nucleus. Neuronophagy is developed feebly in spite of numerous decaying cells and their remainders met in the slide.

XI-th Exp. 9 days after the operation following alterations were noticed:

1) The cells mostly are shrunken forming pericellular spaces; the most shrunken cells are very much diminished, their plasm stains more intensively.

2) Nearly all cells exhibit abundant vacuolation, not only in their periphery but also near the centre. In the lighter cells the plasm is rarefied and contains plenty of various vacuols. The vacuol walls are formed by scarcely staining chromatophile remainders. Some cells are faded all over. In others the tigroid substance is situated in groups near the cell limit.

3) In many cells a distinct pigmentation appears, often occupying more than half of the cell. Under the immersion the pigment proves to consist of numerous yellow brown subtile grains. A similar pigmentation never was to be met in normal cells, in such advanced stages.

4) The nucleus in the majority of the cells has diminished (shrinkage of the nucleus). The greater part of nuclei are situated on the periphery.

V-th and IV-th Exp. 14 days lasting local anemia. Excepting 4 cells all are shrunken considerably and very much diminished in size, exhibiting denticulated margins and intensively staining with blue. The nuclei also are smaller and stain homogeneously (chromatolysis of the nucleus).

In some cells a lucid border round the nucleus is remarkable: a perinuclear space. Most of the nuclei are near the periphery. The nucleolus in some cells is enlarged. The plasm frequently stains diffusely dark blue; sometimes the tigroid substance collects near the cell limit, the middle of the cell staining less intensively. In some cells a small vacuol is visible near the nucleus lining. Decaying cells and neuronophagy also are observable. In several cells the plasm is vacuolated. In others long and thin nerve fibres are visible connecting one cell with the other. The fibres stain well blue. The thicker ones remain uncoloured; the colour of the cell is not extending on the nerve fibres, it interrupts itself suddenly on the outcoming of the fibre.

XII-th Exp. 22 days after the aorta was tied up a great number of cells are perishing. By mediocre magnifying not a single cell is found unaffected. The cells are reduced to a minimal volume manifesting only a small plasm border around the nucleus. In other cells the nucleus even partly exit from the cell. Still other nuclei have fallen out from the plasm and are lying in the surrounding glia. In the rest of the cells the nuclei are lying near the cell limits. Some cells manifest incomplete karyolysis. The nucleus chromatine is collected in groups round the nucleolus. The plasm often is filled with vacuols. In some other cells from the tigroid only traces near the cell limit have remained forming an intensively stained border.

Many cell contain nothing but plasm remainders in little lumps surrounding the nucleus. From the perished cells remained structureless debris. Neuronophagy is not to be seen distinctly.

In the sympathetic ganglia situated above the level, where the aorta was tied up many slight alterations were to be stated as peripheral position of the nucleus and of the tigroid. These ganglia could have been affected only indirectly.

At acute and chronic anæmia quite insignificant results were obtained. The cells scarcely differed from normal ones, only tigrolysis and marginal position of tigroid were noticed. The nuclei were round, pellucid and blisterlike as the normal ones. In a ganglion dorsale of a rabbit the two nuclei of a binuclear cell were shifted to the cell limit.

—:—

The histological preparations proved that degeneration of sympathetic nerve cells is proceeding in a certain order and depends upon the duration of the injurious influence.

First (50 minutes after the operation) in nerve cells appeared simple tumefaction with slight enlarging of the cell body, nucleus and nucleolus. 5 hours after the tying up of aorta the tigroid substance altered. The tigroid grains lost their distinct linings and their coordination in the cell; they mixed up in the plasma and stained darker than normally (incipient tigrolysis).

24 hours after the operation cell shrinkage was appearing. The cells had altered intensively. They had shrunk and contracted; their size was reduced; the plasma stained diffusely. The other cells appeared normal. Decaying cells rarely are observable.

48 hours after the operation the cells are markedly larger, bigger and tumefied. The nucleus lining is indistinct (state of cloudy swelling). Tigrolysis in many cells had become more obvious. Cell decomposition and neuronophagy are to be met oftener.

7—8 days and a fortnight after the operation the alterations were of the same kind but increasing with the life duration after the operation. Shrinkage and diffuse staining of plasma were stated in all cases, simultaneously with loss of tigroid and chromatolysis. Vacuolation very often was noticed. The vacuols mostly were placed near the cell limit and only in exclusive cases vacuols were found in the centre, like in no. VIII. Several cells were decaying and transforming themselves into detritus. The cell dilapidation was accompanied by neuronophagy.

14 days after the operation (experiment V and IV) the greater part of the cells had shrunk markedly while in no. VI, VII and VIII, 3—8 days after the operation besides that copious cells were vacuolated and decaying.

In experiment no. IX the nucleus membrane scarcely was visible and the nucleus chromatin collected itself into small drops and dyed more densely at the periphery. In experiment no. X besides shrinkage an intensive pigmentation was remarked like in no. II and no. III.

22 days after the operation (no. XII) nearly all cells were ruined and only a few remained normal. Tigrolysis, marginal position of

tigroid and of the nucleus were visible in all cases. In two cells by immersion nerve fibres were to be seen; the dense colour of the cells was not extending on to them. The interstitial tissue had not increased judging by the Van Gieson staining.

—:—

Comparing the alterations of sympathetic ganglia obtained by anemia with alterations obtained otherwise, one may conclude that similar alterations were caused by combustion, by starvation and by congelation.

Finishing my essay I will compare in a short way my results with those of Sarbo, Marinisco, Lamy and Pussep, relative to anemia of the central nervous system obtained by compression of the aorta abdominalis or by obturation of the small cerebral arterias. The first authors demonstrated that the process is beginning from the periphery where in a short time tigrolysis is appearing. The chromatophile grains remain safe only around the nucleus. After tigrolysis comes vacuolation, and then the central parts also begin to alter.

The nucleus first is enlarged, then it diminishes and stains homogeneously. The cells then also increase in volume and are tumefied.

The investigations of Professor Pussep I shall report more minutely having obtained concordant results. Prof. Pussep made his investigations on rabbits and dogs, compressing their aorta from one to two hours; in some cases the animals were allowed to live with a ligature on the aorta like in my experiments V. The author reports that the first sign of affection was the collection of the chromatophile granula around the nucleus so that the cell periphery became almost denuded of it. Then the free marginal part of the cell began to stain with methylen blue, later on the nucleus also stained blue and shifted near the cell limit. The chromatine granula then began to decay and the whole cell filled with dust like debris of chromatine granula. Meanwhile the cells remained in their normal size or were slightly enlarged; very probably cloudy swelling was the matter. Then came a stage of swelling and diffuse staining. Next to it shrinking and fading became incipient at the periphery and approached the nucleus; finally the whole cell became faded, only minute chromatine drops somewhere remained.

The third stage was the state of complete dilapidation. The cells changed into granulated masses or shrunk to a minimal volume; finally they wholly disappeared, an empty space indicating the place of the ruined cell.

Another kind of degeneration was represented by vacuolation which usually was proceeding near the cell border.

A third kind of degeneration quite rarely met by the author was fatty degeneration. The fat first appeared at the periphery and then extended to the nucleus; finally the nucleolus also succumbed to fatty degeneration and the cell perished.

The results obtained in my experiments are conformable with those of Prof. P u s s e p (vide the histological part); only fatty degeneration was not met; instead of it I became aware of pigment augmentation.

The same results were obtained by this author in the medulla spinalis by tying up the aorta; he called the alterations „necrobiotic myelitis“.

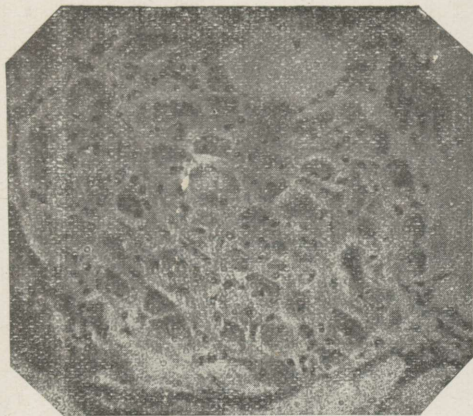
—:—

At the end of my essay I feel compelled to express my deep obligation to my esteemed teacher, P r o f e s s o r L. M. P u u s e p p for having given me the thême and for his kind directives.

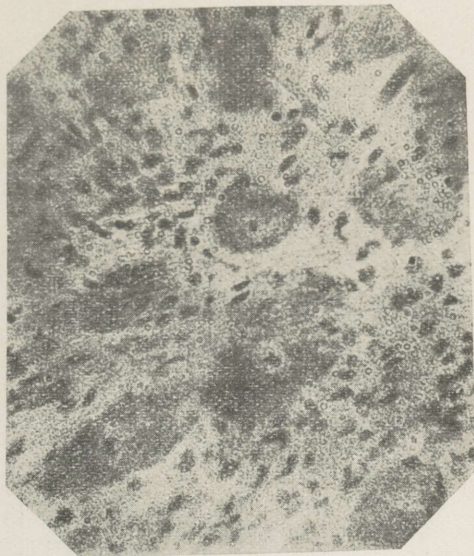
Literature.

- 1) Tanquerel de Planches. Traité des maladies de plomb 1839, quoted after Spiegel and Adolf.
- 2) Brochmann, quoted after Spiegel and Adolf.
- 3) Langley — „Das autonome Nervensystem“. Berlin 1922.
- 4) Staemler — „Zur Pathologie des sympathischen Nervensystems im besonderen über seine Bedeutung für die Entstehung der Arteriosclerose“. 1923 Beiträge zur pathologischen Anatomie und zur allgemeinen Pathologie, B. 71, H. 2, Aschoff.
- 5) Prof. Abrikossoff — „Die Pathologische Anatomie der sympathischen Ganglien“. Virchows Archiv 240, B. 2, 1922.
- 6) Spiegel und Adolf — „Die Ganglien des Grenzstranges“. Arbeiten aus dem neurologischen Institute. XXIII Band, 1 Heft. 1922.
- 7) Korolenko — „On Plexus Solaris Alterations in Cases of Combustion“. Diss. 1897. (Russian.)
- 8) Uskow, quoted after Staemler.
- 9) Rosenbach — „The Influence of Starvation on Nervous Centres“. Diss. 1883. St. Petersburg. (Russian.)
- 10) Issaieff — „Contribution to the Question about the Visceral Ganglia Alterations in Tuberculosis and some other Diseases“. 1887. St. Petersburg. (Russian.)
- 11) Uspensky — „Pathological Anatomical Alterations of some Peripheric Ganglia in Cases of Starvation“. Exper. Invest. Diss. 1896. St. Petersburg. (Russian.)
- 12) Zouboff — „To the Question about Nerve Cell Alterations of Abdominal Sympathetic Ganglia in Starvation“. Diss. Iurieff. (Russian.)
- 13) Statkevitch, quoted by Zouboff.
- 14) Prof. Ignatoffsky — „On the Causes of the Blood Effusions in the Stomach Mucous Membrane in the Cases of Death from Cold“. Vestn. Ssud. Med. (Russian.)
- 15) Anfimoff — „On Central Nervous System Alterations in Animals with Varnished Skin“. Diss. 1887, St. Petersburg. (Russian.)
- 16) Ssemonoff — „To the Sympathetic Nerve Pathology in Typhoid Fever and its Varieties“. St. Petersburg 1873. (Russian.)
- 17) Petroff — „Alterations of the Sympathetic Nervous System in Constitutional Syphilis“. 1871. Diss. (Russian.)
- 18) Mosse M. — „Über experimentelle Bleikolik“. Bericht über Ges. f. Inn. Med. Berlin. Klin. Woch. p. 332.
- 19) Laignel Lavastine — „Recherches sur le plexus solaire“. Thèse 1903, quoted by Spiegel and Adolf.
- 20) Laignel Lavastine — „Contribution à l'étude anatomo-pathologique du Sympathique abdominal dans les infections“. (Revue de med. t. 25, 1905, S. 389). Translation in the „Centralblatt für allg. Pathol. und pathol. Anatomie“. Bd. XVI. 1906.

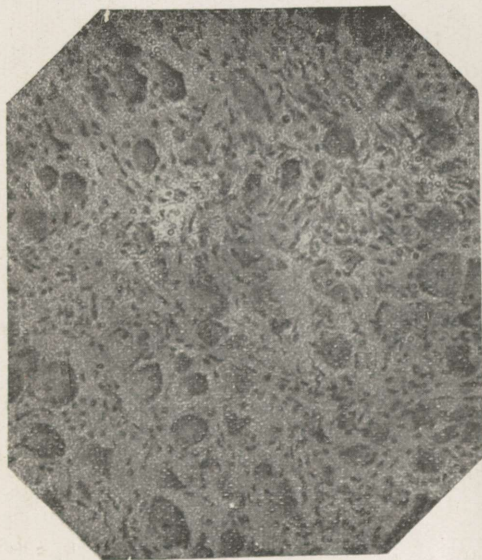
- 21) Kussmaul und Meier — „Zur pathologischen Anatomie des chronischen Saturnismus“. Deutsch. Archiv f. klin. Med. 9.
- 22) Giuzetti, quoted by Spiegel and Adolf.
- 23) Iwanoffsky — „Alterations of the Nervous System in Cholera“. Rudneff's Journal. 1873. (Russian.) Quoted after Korolenko.
- 24) Kollanterians — „Contribution to the Pathological Anatomy of the Plexus Solaris and Plexus Hypogastricus in Peritonitis and Typhoid Fever“. 1881. (Russian.)
- 25) Stomma — „On Pathological Anatomical Alterations of the Heart Ganglia and of the Plexus Solaris in Cholera“. 1893. (Russian.)
- 26) Brugia, quoted by Spiegel and Adolf.
- 27) Satinsky — „Material to the Pathology of the Suprarenal Glands“. Diss. 1872. (Russian.)
- 28) Lancereaux et Leon Gros, quoted by Ssemenoff.
- 29) Bonnet et Poincaré, quoted by Spiegel and Adolf.
- 30) Noera, quoted by Spiegel and Adolf.
- 31) Obersteiner, quoted by Spiegel and Adolf.
- 32) Hirschl — „Die sympathische Pupillenreaction und die paradoxe Lichtreaction der Pupillen bei der progressiven Paralyse“. Wien. klin. Woch. 1899.
- 33) Marina, quoted by Spiegel.
- 34) Cazeneuve, quoted by Spiegel.
- 35) Dalla Vedova — „Experimenteller Beitrag zur Pathogenese des ulcus ventriculi“. Arch. f. Verdauungskr., quoted by Spiegel.
- 36) Gundelfinger — „Klinische und experimentelle Untersuchungen über den Einfluss des Nervensystems bei der Entstehung des runden Magengeschwürs.“ Mitt. a. d. Geb. d. Med. u. Chirurgie. 1918.
- 37) Cavazzani — „Sympathische Veränderungen bei Diabetes mellitus“. Centralbl. f. allg. Pathol. u. pathol. Anat. 1893.
- 38) Dickenson, quoted by Korolenko.
- 39) Bittorf — „Die Pathologie d. d. Nebennieren und d. Morbus Addisonii“. 1908.
- 40) Brauer — „Beitrag z. Lehre v. d. anatom. Veränderungen d. Nervensystems beim M. Addisonii“. Deutsche Zeitschr. f. Nervenkr. 7, 1895.
- 41) Kahlden — „Veränderungen v. symp. Gangl. bei Addison“. Zentralbl. für allg. Pathologie 7, 1896.
- 42) Fleiner — „Über die Veränderungen des sympathischen und cerebrospinalen Nervensystems bei zwei Fällen von Addison'scher Krankheit“. Deuteche Zeitschr. f. Nervenheilk. 2, 1892.
- 43) Ebstein Baucke, quoted by Spiegel.
- 44) Wolf, Andel, Bartsch, quoted by Ssemenoff.
- 45) Ewald — „Ein Fall von M. Addisonii“. Dermatol. Zeitschr. 1894, quoted by Spiegel.
- 46) Virchow, quoted by Ssemenoff.
- 47) Trousseau et Lanceraux, quoted by Ssemenoff.
- 48) Korbut-Daschkewitsch, quoted by Korolenko.
- 49) Gustav Mann, quoted by Korolenko.
- 50) Ssadoffsky — „To the Question about Alterations of Nervous Centres Dependent on Peripheric Irritations“. Diss. 1889. (Russian.)
- 51) Vas Archiv f. mikr. Anat. Bd. XI.
- 52) Eve and Lugaro, quoted by Korolenko.
- 53) Sarbo — „Über die Rückenmarksveränderungen nach zeitweiliger Verschliessung der Bauchaorta“. Neurolog. Centralbl. 1895. Nr. 15.
- 54) Marinesco — „Pathologie générale de la cellule nerveuse“. Quoted by Zouboff.
- 55) Lamy — „Lésions medullaires experimentales produites par les embolies aseptiques“. Quoted by Zouboff.
- 56) L. M. Pussep — „Alterations in the Spinal Cord under the Influence of Compression or Tying up of the Aorta“. 1902. (Russian.)
- 57) Stannius, quoted by L. Pussep.



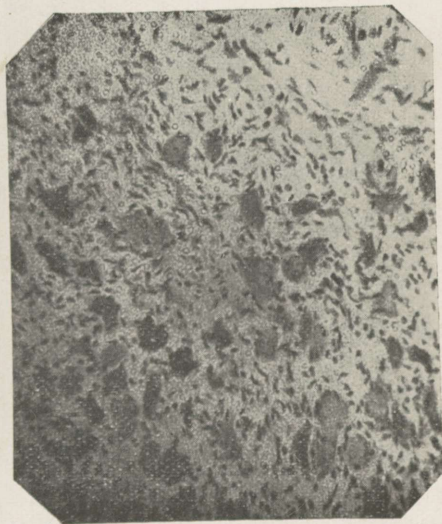
1) *Ganglion mesentericum inferius*. Experiment no. X, Van Gieson staining. Tumefaction of the nuclei. Beginning shrinkage and appearing of pericellular spaces.



2) *Ganglion mesentericum inferius*. Experiment no. III. Thionine staining. Enlarged cells with indistinct contours. Tigrolysis and atrophy of the cell body. Immersion.



3) *Ganglion mesentericum inferius*. Exper. no. V. Thionine staining. Marked shrinkage and homogeneous staining of nerve cells.



4) *Ganglion mesentericum inferius*. Thionine staining. Exp. no. XII. Cells reduced in volume and decaying.

4

ESTICA

A-16179